

1963

# Comparative pathologic, immunologic and clinical responses produced by selected agents of the bovine mucosal disease-viral diarrhea complex

David Earl Tyler  
Iowa State University

Follow this and additional works at: <https://lib.dr.iastate.edu/rtd>

 Part of the [Pathology Commons](#)

## Recommended Citation

Tyler, David Earl, "Comparative pathologic, immunologic and clinical responses produced by selected agents of the bovine mucosal disease-viral diarrhea complex" (1963). *Retrospective Theses and Dissertations*. 2567.  
<https://lib.dr.iastate.edu/rtd/2567>

This Dissertation is brought to you for free and open access by the Iowa State University Capstones, Theses and Dissertations at Iowa State University Digital Repository. It has been accepted for inclusion in Retrospective Theses and Dissertations by an authorized administrator of Iowa State University Digital Repository. For more information, please contact [digirep@iastate.edu](mailto:digirep@iastate.edu).

This dissertation has been 64-3903  
microfilmed exactly as received

TYLER, D.V.M., David Earl, 1928-  
COMPARATIVE PATHOLOGIC, IMMUNOLOGIC  
AND CLINICAL RESPONSES PRODUCED BY  
SELECTED AGENTS OF THE BOVINE MUCOSAL  
DISEASE-VIRAL DIARRHEA COMPLEX.

Iowa State University of Science and Technology  
Ph.D., 1963  
Health Sciences, pathology  
University Microfilms, Inc., Ann Arbor, Michigan

COMPARATIVE PATHOLOGIC, IMMUNOLOGIC  
AND CLINICAL RESPONSES PRODUCED  
BY SELECTED AGENTS OF THE  
BOVINE MUCOSAL DISEASE-VIRAL  
DIARRHEA COMPLEX

by

David Earl Tyler, D. V. M.

A Dissertation Submitted to the  
Graduate Faculty in Partial Fulfillment of  
The Requirements for the Degree of  
DOCTOR OF PHILOSOPHY

Major Subject: Veterinary Pathology

Approved:

Signature was redacted for privacy.

In Charge of Major Work

Signature was redacted for privacy.

Head of Major Department

Signature was redacted for privacy.

Dean of Graduate School

Iowa State University  
Of Science and Technology  
Ames, Iowa

1963

## TABLE OF CONTENTS

	page
INTRODUCTION	1
REVIEW OF LITERATURE	3
MATERIALS AND METHODS	17
Calves	17
Diet	17
Housing	17
Infective Agents	19
Preinoculation and Inoculation Procedure	22
Clinical Observations	23
Hematologic Procedures	24
Necropsy Procedure	24
RESULTS	27
Clinical Observations	27
Hematologic Observations	38
Gross Pathologic Observations	42
Histologic Observations	53
Immunologic Observations	104
DISCUSSION	114
Infective Agents	114
Clinical and Hematologic Responses	115
Pathology	119
Combined Inoculations	126
Concluding Statements	127

	page
SUMMARY	129
LITERATURE CITED	133
ACKNOWLEDGEMENTS	138

## INTRODUCTION

The identification of virus diarrhea in cattle as a disease entity was first made by Olafson et al. in 1946. Soon after this report, a number of similar bovine conditions was observed. These included X-disease of cattle-Saskatchewan (Childs, 1946), mucosal disease-Iowa (Ramsey and Chivers, 1953), virus diarrhea-Indiana (Pritchard et al., 1954), an acute upper respiratory infection of dairy cattle-California (Schroeder and Moys, 1954), an influenza-like entity-California (McKercher et al., 1954) and infectious necrotic rhinotracheitis of cattle-Colorado (Miller, 1955). The last three conditions were later recognized as a single syndrome and designated as infectious bovine rhinotracheitis.

Because of the marked similarity between these conditions and a lack of information concerning their specific etiologic agents, they were grouped together by the Agricultural Research Service in 1955 under the designation of mucosal disease complex (USARS report 1956).

Infectious bovine rhinotracheitis (IBR) was the first of the group for which a specific etiologic agent was identified and by 1960 was recognized as a separate entity. Since then, serologically related cytopathogenic agents have also been isolated from field cases of mucosal disease and virus diarrhea.

The principal research efforts following these isolations have been directed toward the further characterization of these agents in vitro. Little work has been conducted to explain the wide variations in the clinical syndromes produced by these serologically similar agents in naturally occurring cases. Members of the complex have been routinely

differentiated in the field on the basis of morbidity and/or mortality rates, the course of the disease and gross pathologic observations.

This study was undertaken to compare certain isolants selected from the complex. The comparison was based on the clinical and immunologic responses, and on the pathologic changes occurring in calves inoculated with these agents.

## REVIEW OF LITERATURE

A thorough review of the literature concerning the mucosal disease-viral diarrhea complex was made by Trapp (1960). The literature review for this study will be primarily confined to those articles dealing with the characteristics of the various agents that have been isolated from field cases of the complex.

Olafson et al. (1946) reported that an apparently new disease of cattle, which they later named virus diarrhea, could be transmitted experimentally to calves. Infective material was obtained from blood, feces and splenic emulsion. The mode of transmission was 5 ml subcutaneous inoculations of infective blood.

Symptoms observed in infected calves consisted of a temperature elevation lasting from three to six days, leukopenia on the fourth or fifth day, salivation and nasal discharge from the ninth to the fourteenth day and diarrhea from the tenth to the fourteenth day. Not all animals developed diarrhea. One to three days after the diarrhea developed, ulcers appeared in the mouth. Anorexia and adipisia were evident. Some animals died shortly after the diarrhea became noticeable. Post mortem lesions observed were ulcerations of the oral mucosa, tongue and esophagus; hyperemia of the stomachs and intestine; petechial hemorrhages and a few erosions in the abomasum and cecum. Material regularly infective for calves failed to produce recognizable symptoms in rabbits, mice, guinea pigs, sheep or ten-day-old chicken embryos.

Olafson and Rickard (1947) and Walker and Olafson (1947) conducted a series of experiments to determine the immunologic relationship of



the newly identified virus diarrhea agent to rinderpest. Both serum neutralization and protection tests were carried out. These investigators could show no relationship between the two viruses.

Wheat et al. (1954) isolated an agent from a field condition the syndrome of which was similar to that described by Olafson (1946). Cross protection tests revealed that this agent was immunologically related to the New York virus diarrhea isolant.

McKercher et al. (1954) compared the New York strain of virus diarrhea with the newly recognized influenza-like disease of cattle (later to become identified as infectious bovine rhinotracheitis). Although the study was limited in scope and results were not decisive, they concluded that the two conditions were not immunologically related.

Baker et al. (1954) reported the isolation of two strains of virus from field cases of a disease resembling that described by Olafson et al. (1946). On this basis they concluded that their isolants were similar to Olafson's original isolant. They stated that it was not possible to compare them with the original infectious material since it had not been preserved. Intravenous or intranasal inoculations of infective blood and splenic emulsion were used in their studies. The clinical syndrome was characterized by a rise in temperature from the second to the fourth day and again from the sixth to the ninth day after inoculation. The second rise was more pronounced than the first. A transient leukopenia was sometimes observed on the third day postinoculation. In most calves a definite leukopenia was observed during the period of the second temperature rise. Occasionally an uninterrupted leukopenia would be present from the time of the initial temperature rise. Animals continued

to eat and drink during the first temperature rise but refused both food and water and became quite depressed during the second rise. Increased lacrimation was observed in some calves. Diarrhea was not a consistent finding. Oral lesions were observed infrequently.

None of the animals infected died and as a rule generally returned to eating after the drop in fever. Of two pregnant cows infected, one aborted six weeks after infection; the other went to full term.

Necropsy examination of twenty-one calves revealed no changes that could be attributed to virus diarrhea except for three calves that had ulcers in the oral mucosa. "Reddening" of the stomach and the intestines was observed in some calves. Histologic study of the liver, lungs, spleen, kidneys and intestines revealed no lesions. Inclusion bodies were not seen.

Baker adapted the virus to rabbits by serial passage. After the thirtieth passage the virus began to modify and by the seventy-fifth passage was considered to be avirulent but immunogenic when inoculated into susceptible calves. Chicken embryos, guinea pigs, swine, dogs, cats, goats, sheep, and mice were found to be refractive to the virus.

Cell cultures were successfully employed by Lee and Gillespie (1957) to propagate the New York strain 1 of virus diarrhea originally isolated by Baker et al. (1954). The virus was carried for twenty serial passages in skin-muscle cell cultures and fifteen additional transfers in embryonic bovine kidney cells. Although no cytopathic effect was observed, the passaged virus was found to be fully virulent for calves at dilutions of  $10^5$  to  $10^7$ .

Gillespie and Baker (1959) compared strain 1 of New York virus diarrhea with strain 46 Indiana virus diarrhea. Their studies showed a definite immunologic relationship and an identical experimental syndrome for both of these viruses. They were also able to propagate the Indiana strain in embryonic bovine kidney cell culture. As with the New York strain, a cytopathic effect was not observed.

Gillespie et al. (1960) isolated a cytopathogenic agent from spleen sent to their laboratories from a field case of virus diarrhea which had occurred in the state of Oregon. The agent was grown on embryonic bovine kidney cells where it produced rounding of the cells within six to eight days incubation and detachment of the cell sheet by twelve to fifteen days. They named this agent Oregon C24V. Cross immunity trials showed that it was closely related to the New York strain 1 of virus diarrhea. The clinical syndrome produced by the agent was not described. Serum neutralization tests indicated not only a relationship with the New York strain but also with the Indiana 46 strain of the virus.

In a study to determine the value of the neutralization test as an indicator of immunity, Robson et al. (1960) inoculated fifty-nine calves with a viral diarrhea virus. Although it was not definitely stated, it is assumed that this virus was the Oregon C24V strain. Following these inoculations the calves reportedly developed, "-typical signs of virus diarrhea, characterized by diphasic temperature elevation and leukopenia."

Pritchard et al. (1954 and 1955) recognized a condition in Indiana cattle which closely resembled virus diarrhea as described by Olafson in New York. From the blood of one of these animals an agent was isolated

which produced the disease in its entirety under laboratory conditions. In a later report this agent was designated Indiana VD 143 (Pritchard and Kniazeff 1958). No immunologic relationship was seen when cross protection tests between the New York and Indiana VD 143 strains were compared. Sheep, mice, guinea pigs, rabbits or chicken embryos failed to respond clinically when inoculated with the new agent.

A later report by Pritchard and Carlson (1957) stated that the Indiana virus diarrhea agent would infect rabbits, sheep and young swine. Dogs, cats, guinea pigs, goats and chicken embryos, however, remained refractive. Blood or spleen taken during and shortly after the period of leukopenia were found to contain the infective agent. Oral, intranasal, rectal, subcutaneous, intramuscular, and intravenous routes of inoculation were found to be effective in transmitting the disease. Unfortunately this agent was lost (Pritchard and Kniazeff, 1958).

Carlson et al. (1957) reported more extensively on the experimental disease produced by the Indiana virus diarrhea agent. The study included clinical and pathologic examination of twenty experimentally infected calves. Inoculations consisted of 5 ml of defibrinated blood given intravenously. A diphasic pyrexia was observed. The first rise of one to three degrees, which was occasionally delayed or even missing, occurred on the third day postexposure. The second rise was observed on the seventh or eighth day postinoculation. This rise was more marked than the first with readings three to five degrees above preinoculation levels. A leukopenia occurred at the time of the first temperature rise. Leukocyte levels tended to remain depressed until after the second temperature elevation. During the febrile period the calves were

depressed, off feed, and developed a dry cough and serous nasal discharge. One third of the animals became lame. Diarrhea usually appeared during the second temperature rise and persisted for an average of five days. Oral lesions appeared at the same time in ten of the calves. In three calves, exacerbations and remissions of clinical signs were noticed at two-week intervals for two to three months after inoculation. No deaths occurred.

Gross lesions according to Carlson consisted primarily of multiple focal erosions of the oral mucosa, esophagus and infrequently the rumen, omasum and abomasum. A catarrhal enteritis associated with congestion, hemorrhage and edema of the mucosa was observed in the intestines. The duodenum was the most severely involved. Peyer's patches and lymph nodes were enlarged and edematous.

Histologic examination of the affected stratified squamous epithelial surfaces of the upper digestive tract revealed sharply demarcated lesions. Some of the lesions extended through the basal cell layer as well as to the surface. The initial involvement occurred in the cells just above the germinal layer. The affected cells had pyknotic and fragmented nuclei and homogeneously pink-stained vacuolated cytoplasm.

Carlson noted considerable loss of surface epithelium, edema of the mucosa, and atrophy and dissociation of the cells lining the crypts of the abomasum. Necrosis of the tips of the villi with loss of surface epithelium was commonly seen in sections of the small intestine. Pronounced dilatation of the lymph spaces and edema between the degenerative and desquamating surface epithelium and the stroma of the villi was usually observed. Similar changes were seen in the cecum, colon and

rectum. Histologic examination of the lymphatic tissues revealed lymphoid exhaustion and edema in the majority of the calves affected. In the spleen depleted germinal centers were also observed.

Included in Carlson's study was a comparison of virus diarrhea lesions with those found in tissues collected from ten field cases of mucosal disease. It was his opinion that the pattern of involvement was quite similar in both conditions. The difference appeared to be in the greater degree of severity of the lesions in animals affected with mucosal disease. He pointed out that the necrosis and sloughing of Peyer's patches which is characteristic of mucosal disease had not been observed in cases of Indiana virus diarrhea. It is not clear whether the agent used in this study was the original Indiana VD 143 or a later isolant designated as Indiana 46 (Gillespie and Baker, 1959) or a different isolant than either of these.

Schipper et al. (1955) reported successful transmission of mucosal disease by intramuscular inoculation of blood obtained from a naturally infected animal. The experimental syndrome was considered to be very mild and was characterized by lacrimation, salivation, nasal discharge, elevated temperature, anorexia and mild diarrhea. The symptoms appeared between the fourth and tenth day postinoculation and persisted for twelve to thirty-six hours. Intermittent recurrences of one or all of these symptoms appeared in some calves. Attempts to transmit the agent to swine, sheep, guinea pigs, rabbits, hamsters, white mice, white rats, young chicknes or chicken embryos were unsuccessful. Work with this agent was apparently dropped in favor of the one described in the

following paragraph.

Noice and Schipper (1959) isolated a cytopathogenic agent from a composite sample of lymph node, spleen and blood taken from an animal affected with the field syndrome of mucosal disease. The isolation was made on bovine kidney cells. Intravenous inoculation of this agent into susceptible calves produced a mild disease characterized by slight temperature elevation from the sixth to tenth day postinoculation. One calf developed a diarrhea of two days duration. This agent has been referred to as the North Dakota (BMD) agent.

Barner et al. (1960) reported a more extensive characterization of the experimental syndrome produced by the cytopathogenic North Dakota agent. Forty-eight hours after inoculation with this virus the temperature rose about three degrees above the preinoculation level and remained near that level for about four days. A leukopenia of about fifty per cent occurred at the time of the temperature rise. Ocular discharge and congestion of the oral and nasal mucosa were rarely seen. Diarrhea did not occur. Routes of inoculation included intravenous, intranasal, intramuscular, intraocular, oral, subcutaneous, intracutaneous or rectal.

They observed a catarrhal to catarrhal-hemorrhagic enteritis in the posterior half of the small intestine, edema and hyperemia in the mesenteric lymph nodes and Peyer's patches, petechial hemorrhages and/or erosions in the fundic portion of the abomasum, ecchymoses in the adrenal cortices, and occasional necrotic foci in the epithelium above Peyer's patches. Histologic changes included hemorrhagico-necrotic alterations in the affected areas of the small intestine and necrotic foci and peritrabecular lymphoid infiltrations. Lymphocytic depletion, reticulohistiocytic

proliferation, edema and congestion were noted in the affected lymphatic tissues.

Schipper (1961) concluded that the mucosal disease agent (MDA-ND) was similar or identical to IBR virus on the basis of serological and agar diffusion evaluations. As far as can be determined by this investigator it appears that the MDA-ND agent is the same as the BMD agent isolated by Noice and Schipper in 1959.

Pritchard (1955) isolated an agent from the blood of cattle affected with mucosal disease. Inoculation of susceptible calves produced a diphasic temperature elevation, leukopenia, depression, lacrimation, nasal discharge, oral erosions and diarrhea. The response to this agent was similar to that produced by virus diarrhea. This agent was lost soon after this work was reported.

Although Ramsey (1956) reported that his transmission attempts with mucosal disease were inconclusive, re-evaluation of the data indicates that many of the responses were just as marked as those reported in other investigations. None of the infective material was saved from Ramsey's work.

Underdahl et al. (1957) described the isolation of two cytopathogenic agents from field cases of mucosal disease. The agents were isolated from composites of tissue taken from diseased animals. The agents were grown on bovine kidney cell cultures. The initial changes in the cells occurred as small vacuoles in the cytoplasm seven to ten days after inoculation. Within three to four days the cell sheet was completely destroyed. Cross neutralization tests in cell cultures indicated that these two agents were closely related. One was designated M-833 and



the other ISC-1. Inoculation of these agents into calves was not reported.

Claflin et al. (1961) reported the isolation of a cytopathogenic agent which had been erroneously mistaken for the Nebraska M-833 agent. The agent was apparently a contaminant in either the material sent from the Nebraska laboratory or the tissues used in the cell cultures at the Purdue University laboratory. Before the error was discovered, considerable characterization of the contaminant had been performed. Inoculation of calves produced a monophasic high temperature, leukopenia and depression. Serum neutralization studies indicated a possible relationship to the IBR virus but none to the Oregon C24V virus. The relationship to the IBR virus was not considered reliable since it was based on a single sample of serum taken from a calf. IBR serum produced in rabbits did not neutralize the Nebraska agent. The contaminating agent was given the designation of C-1.

Tyler (1960) reported the isolation of an agent from a field case of mucosal disease in Indiana cattle. The isolant was named the Merrell agent in deference to the owner of the herd from which the isolation was made. Inoculation of this agent into calves was characterized by a diphasic temperature elevation on the third and seventh days, leukopenia of about sixty per cent on the third day, depression and mucous nasal discharge from the third to the eleventh day, diarrhea on the eighth day, and anorexia on the third day and again from the sixth through the ninth day. Pin-point vesicles were observed on the oral mucosa between the eighth and eleventh day.

Richter (1962) reported the isolation of an agent from a field case of mucosal disease in Iowa cattle. The agent was named the Sanders agent

out of courtesy for the owner of the herd from which the isolation was made. The clinical reaction in calves following inoculation of this agent was variable and mild. It was characterized by leukopenia, fever, depression, anorexia and abdominal pain. Gross lesions consisted of esophageal ulcers, catarrhal enteritis and considerable amounts of fibrin-rich fluid in all serous cavities. Edema was seen in the abomasum, the hyperplastic Peyer's patches, ileum, colon and lymph nodes. Histologic examination substantiated the gross findings. In addition there was lymphoid depletion and necrosis of lymphoid nodules of Peyer's patches and many lymph nodes. Fibrin was observed filling many lymphatics of the wall of the ileum. In Richter's opinion the tissues affected and pattern of effect produced by the Sanders agent were similar to those seen in natural cases of mucosal disease. He was unsuccessful in his attempts to adapt the agent to rabbits and various cell cultures.

Agents isolated from natural cases of mucosal disease which produce experimental diseases similar to that described for the New York strain 1 of virus diarrhea have been reported in England by Dow et al. (1956) and Huck (1957).

Bakos and Dinter (1960) reported the isolation of a cytopathogenic agent from nasal and tracheal exudates from natural cases of mucosal disease in Sweden. A mild form of the field syndrome was produced when this agent was inoculated into susceptible calves. Cross neutralization tests revealed a close relationship to the HA-1 strain of parainfluenza.

Kniazeff and Pritchard (1960) conducted a series of serum neutralization tests using the Oregon C24V virus. The plaque assay method was used for this work. Pre- and postinoculation sera were obtained primarily

from experimental cases of mucosal disease and viral diarrhea. Samples of mucosal disease antisera were obtained from Iowa, Indiana, North Dakota and England. Viral diarrhea sera was supplied from New York, Indiana, Florida and Nebraska. Test results indicated a definite and close relationship between the Oregon C24V agent and all the antisera used in the study. Neutralization tests were also performed with sera from cases of bluetongue, malignant catarrhal fever, infectious bovine rhinotracheitis, hog cholera, infectious ulcerative stomatitis, sporadic bovine encephalitis, mycotic stomatitis and winter dysentery. No serologic relationship could be shown between these conditions and the Oregon C24V agent.

An additional test using pre- and postinoculation mucosal disease sera originating from West Germany was reported by Kniazeff et al. (1961). These sera were also capable of neutralizing the Oregon C24V agent. Including the results from the first study (Kniazeff 1960), they concluded that an antigenic relationship exists between the Oregon C24V virus and viral diarrhea-mucosal disease complex viruses from various parts of the world. They emphasized that although a relationship does exist, it does not imply that all of the agents involved as causative factors in the viral diarrhea-mucosal disease complex are identical or are related.

Gillespie et al. (1961) using pre- and postinoculation sera from calves experimentally infected with New York strain 1 of virus diarrhea conducted a series of serum neutralization tests against several cytopathogenic agents. The agents used were Oregon C24V, a Nebraska virus diarrhea strain, a Nebraska mucosal disease strain, and three new virus diarrhea isolants from New York designated as C55F, C60F and C80K.

All agents were neutralized by the antiserum from New York strain 1 of virus diarrhea.

Gillespie et al. (1962) gave further evidence of the serologic relationship of various agents of the mucosal disease-viral diarrhea complex. Using an interference test it was shown that several noncytopathogenic agents could prevent the cytopathic activity of the virus diarrhea strain C60F. These agents were New York strain 1 virus diarrhea, Indiana 46 strain of virus diarrhea and Sanders strain of mucosal disease. Antisera from a calf experimentally infected with the New York strain 1 virus neutralized the interfering activity of these agents.

Taylor et al. (1963) compared several agents of the mucosal disease-viral diarrhea complex concerning their serologic, clinical and immunologic properties. The agents used were Oregon C24V, Nebraska M-833, Indiana 46 virus diarrhea, Merrell, Sanders, North Dakota (BMD), and New York 1 virus diarrhea. Clinical observations and cross protection tests were reported for only the Oregon C24V, Merrell, and Indiana 46 virus diarrhea agents. Clinically the reactions were quite similar. The clinical response was characterized by fever, depression, serous nasal discharge, anorexia and leukopenia on the third day following inoculation. From the fourth to the sixth or eighth day the calves appeared relatively healthy. Around the sixth or seventh day the temperature rose again and the clinical manifestations reappeared. In addition diarrhea lasting from one to five days was observed in a few animals. The response to the Oregon C24V agent was noticeably milder than with the other two agents. Cross protection tests revealed an immunologic relationship

between the three agents. Serum neutralization studies revealed a serologic relationship between all the mucosal disease-viral diarrhea agents used in this study and the Oregon C24V agent. Some relationship also was observed between IER antiserum and the test virus, but none was observed between the para influenza I and III, ECHO20, ECHO28, bovine enterovirus 1 or adenovirus T3. It was suggested that the Oregon C24V agent might be placed in the adenovirus group on the basis of its size, ether stability, (disputed by Gillespie et al. 1963 and Hermodsson and Dinter 1962) lack of hemadsorption, refractiveness for chicken embryos and other laboratory animals, heat lability, and effect on cell culture.

An antigenic relationship of the mucosal disease-viral diarrhea complex to hog cholera has been shown by several workers (Darbyshire 1960, Beckenhauer et al. 1961, and Sheffy et al. 1961). Although there is antigenic relationship, it does not appear that the shared antigens participate in the virus-serum neutralization phenomenon (Kniazeff and Pritchard 1960). Sheffy et al. (1961) suggest that the reciprocal protection produced in calves and swine from the inoculation of a virus diarrhea agent or hog cholera virus is due to a heterotypic secondary response. In other words, specific antibody production against an agent begins much sooner if there has been a prior experience with an antigenically related agent. Gutekunst and Malmquist (1963) have shown that the relationship between viral diarrhea and hog cholera is due to a soluble antigen rather than the infectious component. They suggest that the system described by Sheffy et al. (1961) may be due to the antibody response to the soluble antigenic component.

## MATERIALS AND METHODS

## Calves

A total of 94 Holstein male calves were used in this study. Five were purchased from the dairy herd at the Eldora Training School for Boys at Eldora, Iowa. Twelve were obtained from the Oakdale Sanitarium dairy herd at Oakdale, Iowa. The remainder originated from the dairy herd at the Woodward State Hospital at Woodward, Iowa. These are considered to be closed herds and at the time of our purchases had had no record of disease that would be classified in the mucosal disease-viral diarrhea complex. The calves from the Oakdale herd, however, were found to be refractive to the Sanders mucosal disease agent and no further purchases were made. The calves from the Eldora herd were susceptible to the agents used, but changes in management at the school eliminated this herd as a source of calves. The calves from the Woodward herd were fully susceptible to all agents used in this study.

The calves were subjected to experiment usually between three and four months of age. The number of calves used for each phase of the study is given under the section covering results.

## Diet

All calves received the same diet composed of the following: cracked yellow corn-43%, crimped oats-29%, dehydrated alfalfa pellets-15%, soybean oil meal-12%, salt-1/2%, dairy mineral-1/2%. The calves were hand fed an amount that they would completely consume twice daily. The ration was ground and mixed by a local feed mill.

## Housing

Calves were housed in one of three areas. This was necessitated by a shortage of suitable quarters for isolation of infected animals. During

the summer months most of the calves were confined in open shelters which had been placed in isolation lots at the Veterinary Medical Research Institute. The only isolation that such units could provide was distance of approximately fifty feet from other animals. Other than the enclosure gates, the shelters were open on all sides. Ground corn cobs were used for bedding. The shelters and all utensils were thoroughly cleaned with a lye solution and disinfected with a quaternary ammonium compound between each group of calves. After being cleaned the shelter was moved to a clean area within the isolation lot. Despite the **simplicity** of such facilities, trouble from cross infection did not occur.

During the remainder of the year and to some extent during the summer, calves were housed either in the isolation building at the Veterinary Medical Research Institute or in the research laboratory of the Veterinary Pathology Department. The isolation units at the Institute are constructed of concrete as far as the floor and lower third of the walls are concerned. The rest of the walls are covered by plaster. A wooden partition divides the unit into a service area and an animal pen. A drain is present in the floor of the pen. Each unit contains a window and door which opens to the outside of the building. The air for the unit comes from these openings. Bedding was not used in these pens. These units were thoroughly cleaned, disinfected, sealed and fumigated with formaldehyde gas between groups of calves.

Wooden gates or metal fencing panels were placed on the concrete floor of the Veterinary Pathology research laboratory animal room to form holding pens. No bedding was used. The floor, panels, walls and utensils were thoroughly cleansed with lye solution and disinfected

with quaternary ammonium compound between groups of calves. Fumigation could not be used in this area.

#### Infective Agents

The following infective agents were used in this study:

##### Sanders agent

This agent was isolated in Iowa from an animal affected with mucosal disease and was originally prepared as a ground suspension of lymph node, abomasum, small intestine in the area of Peyer's patches, liver, spleen and kidney (Richter, 1962). Later it was found that defibrinated blood taken from calves infected with this suspension during and shortly after the peak of the clinical reaction contained the infective material (Richter, 1962). For this study defibrinated blood was routinely saved from calves infected with the Sanders agent and used as the inoculum for succeeding experiments. The blood was placed in rubber stoppered glass test tubes and stored at  $-40^{\circ}\text{C}$  until needed.

##### Merrell agent

This agent was isolated in Indiana from defibrinated blood taken from a yearling Hereford heifer affected with mucosal disease (Tyler, 1960). The agent was recoverable from the blood of infected experimental calves at and shortly after the peak of the clinical reaction. In this study defibrinated blood was taken from infected calves and placed in rubber stoppered glass tubes and stored at  $-40^{\circ}\text{C}$  for succeeding trials.

##### Indiana virus diarrhea 46 agent (IVD 46)

This agent was recovered from a field outbreak of virus diarrhea in Indiana. Defibrinated blood taken from these animals and inoculated into calves produced signs of virus diarrhea (Gillespie and Baker, 1959).



The original inoculum used in this study was obtained from the Department of Microbiology and Public Health at Purdue University. Defibrinated blood was routinely collected during the peak of the clinical response following inoculation of calves and stored in rubber stoppered glass tubes at  $-40^{\circ}\text{C}$  for use in succeeding trials.

National Animal Disease Laboratory - mucosal disease agent (NADL-MD)

This agent was isolated from a field case of mucosal disease which occurred in the experimental herd of cattle at the National Animal Disease Laboratory at Ames, Iowa. The virus was isolated in primary bovine embryo kidney cell culture from a multiplicity of tissues, rectal swabs and nasal swabs. It produced a cytopathic effect on the cell culture (Gutekunst, and Malmquist, 1963).

The inoculum used in this study was obtained from the mucosal disease research unit at the National Animal Disease Laboratory as the second passage cell culture material.

North Dakota (BMD) agent

This agent was isolated from a field case of mucosal disease in North Dakota. The agent was isolated in bovine kidney monolayer cell culture from spleen and a combination of spleen, lymph node and whole blood taken from the affected animals. The agent produces a cytopathic effect on cell culture. Inoculation of the cell culture cultivated agent into calves produces a syndrome suggestive of early mucosal disease (Noice and Schipper, 1959).

The original inoculum used in this study was obtained from the Department of Pathology at Michigan State University as a cell culture of the agent. This source was used because the agent from the Department

of Veterinary Science at North Dakota State College was unavailable at the time. Additional inoculum was supplied by Van Der Maaten of the Department of Veterinary Hygiene, Iowa State University.

Near the end of this study suspicions arose concerning the relationship of this agent to the infectious bovine rhinotracheitis (IBR) virus. Reciprocal serum neutralization tests indicated that this agent is a strain of the IBR virus.\*

#### Nebraska agent (C-1)

This agent was originally mistaken for the M-833 cytopathogenic agent isolated from a multiplicity of tissues taken from a field case of mucosal disease in Nebraska (Underdahl and Grace, 1957). Workers at Purdue University had requested the M-833 agent for a series of studies on various cytopathogenic mucosal disease agents. It was later discovered that, although this agent was cytopathic and would produce a syndrome in calves, the pattern of cell destruction and response in calves was different from that originally described by the Nebraska workers. Neutralization trials with serum obtained from calves infected with the M-833 agent in Nebraska revealed that a contaminant was being studied. Claflin et al. (1961) labeled this agent as C-1 (contaminant number one).

Since we were in close contact with the work being done at Purdue, our original supply of Nebraska agent was obtained from them. Unfortunately much of our work with this agent was completed before the

---

\*The serological study of this agent and the Nebraska agent were performed by C. P. Peter, B.V.Sc., Research Assoc., Department of Veterinary Pathology, Iowa State University.

discovery of the contamination was made. Since our work had shown a close relationship between this agent and the North Dakota agent and since both produced a syndrome in calves suggestive of an early mucosal disease infection, it was decided that they should be retained in the study.

The inoculum for this study was infective cell culture material supplied by Van Der Maaten, Department of Veterinary Hygiene at Iowa State University.

Because this agent appeared to be closely related to the North Dakota agent, it too was subjected to reciprocal serum neutralization tests with the IBR virus. It was also found to be a strain of the IBR virus.

#### Infectious bovine rhinotracheitis (IBR) virus

The strain used in this study was obtained indirectly from Colorado by way of the Iowa Veterinary Diagnostic Laboratory and the National Animal Disease Laboratory. The strain was regarded as being fully virulent for calves. Its infective titer in cell culture was between  $10^5$  and  $10^6$ . The inoculum used in this study was infective cell culture material which had been held at  $-20^{\circ}\text{C}$  for about two months after its harvest.

#### Preinoculation and Inoculation Procedure

All calves were given sufficient time to accommodate to their new environment before being placed on experiment. Twice daily observations were made at this time to determine their state of health. No calf was placed on experiment until it was considered to be in a good state of health.

Once the calf was placed on experiment, a preinoculation period of three to six days was provided for each calf. During this period blood samples were taken daily and temperatures recorded twice daily. When a sufficiently stable level had been established the calf was inoculated.

With a very few exceptions all inocula were taken from storage at  $-40^{\circ}\text{C}$ . They were rapidly thawed by rolling the tube between the hands. Intravenous inocula included 5 ml of defibrinated blood and/or 3 ml of cell culture. Two calves received inoculations intranasally. These consisted of 3 ml of tissue culture inoculum.

In the cross immunity studies the challenging inoculation was not made until two weeks after the initial inoculation. Presence of immunity was indicated by the lack of clinical or hematological changes characteristic of the syndrome normally produced by an inoculation of the challenging agent.

In those trials where combinations of agents were used, the most common method was to inoculate one agent and immediately follow with the other. In two trials one to three days were allowed to elapse between the two inoculations. A more specific description of these two trials is recorded in the section covering results.

#### Clinical Observations

Following inoculation, the calves were observed twice daily for signs of infection. During these observations a blood sample was taken and the temperature was recorded. Any deviation from the calf's usual condition was noted. The observation period usually lasted for ten days unless it was to be followed by a challenge at the end of two weeks, in which case it continued on through the challenge. Calves

that were destroyed for pathological examination had observation periods of variable length. Reasons for this variability are given in the section on necropsy procedure.

#### Hematologic Procedures

A 5 ml oxalated blood sample (a mixture of potassium and ammonium oxalate with a final concentration of 1% in blood) was obtained from each calf as prescribed by the observation schedule. A blood smear was made directly from the needle used for the venapuncture.

Total and differential leukocyte counts were done in accordance with the methods recommended by Benjamin (1958). The acid hematin method (Sahli 1905) using the procedure recommended by Fister (1950) was employed for hemoglobin determinations. Readings were made on the Coleman Jr. Spectrophotometer, model 6A.\*

Hematocrit readings were made with microhematocrit tubes using an International Hematocrit Centrifuge.\*\*

#### Necropsy Procedure

Depending upon the degree and speed of the reaction, calves were euthanatized for pathologic examination usually between the seventh and tenth days postinoculation. Previous work with several of these agents (Carlson et al. 1957, Tyler, 1960, and Richter, 1962) indicated that the pathologic changes should be at their peak during this time. Calves infected with the Nebraska and North Dakota agents were generally euthanatized between the fifth and seventh day postinoculation due to the more

---

\*Manufactured by Coleman Instruments, Inc., 318 Madison Street, Maywood, Illinois.

\*\*Manufactured by International Equipment Co., 1285 Soldiers Field Road, Boston, Mass.

rapid course of the syndrome produced by these agents. Two calves inoculated with Sanders agent were killed on the fourth and fifth days postinoculation in an attempt to determine if inclusion bodies were formed early in the course of the disease.

All calves were euthanatized by electrocution and immediately subjected to necropsy. Gross observations were promptly recorded and pictures taken of significant lesions.

Sections for histologic examination were routinely taken from the following tissues: esophagus, rumen pillar, abomasum, duodenum, jejunum, ileum, colon, mesenteric lymph nodes, spleen, thymus gland, liver, kidneys and adrenal glands. These tissues were selected because past experience with both the field and experimental syndromes indicated that lesions might occur at these sites.

The sections from the jejunum and ileum included a portion of a Peyer's patch. The mesenteric lymph nodes were taken from the mid-jejunal and terminal ileal regions. The colon sections were taken at the point where the colon enters the ansa spiralis. At this point a large area of lymphoid tissue is present in the submucosa.

All tissues were placed in individual vials containing 10% buffered formalin and allowed to fix for at least 48 hours before they were trimmed, dehydrated, cleared and embedded in paraffin. Sections were cut at 6 microns and mounted on albuminized slides. All sections were routinely stained with hemotoxylin and eosin. Special staining procedures were used on selected tissues. Gomori's iron reaction was carried out on paraffin sections of spleen. Selected sections of adrenal gland were stained with Von Kossa's stain. Mucicarmine stain was used on a few

sections of colon. The above procedures were carried out as suggested by the Armed Forces Institute of Pathology (1957).

Sections from comparable tissues were taken from twenty apparently healthy calves at the Iowa State University meat laboratory. These sections served as comparison controls.

## RESULTS

## Clinical Observations

Sanders agent

Twenty-two calves were used in this phase of the study. The clinical response was characterized by the following:

Between the second and fifth day the temperature would usually rise from one to three degrees. In some calves this first temperature rise was occasionally lacking. From the fifth day and until the sixth or seventh day the temperature remained slightly elevated. Following this brief remission, a definite rise occurred from the sixth to the ninth day. This elevation was more marked than the first and revealed an increase of two to five degrees above preinoculation levels. By the end of the ninth day the temperature returned to the limits of the preinoculation level. These values are shown graphically in Figure 1.

With the initial temperature rise the calf became mildly depressed and developed a mild to moderate mucous nasal discharge. Mild lacrimation was also occasionally observed at this time. These conditions usually persisted until the second peak in temperature when they again became more prominent. Anorexia varying from mild to complete loss of appetite occurred during both febrile phases of the infection. Diarrhea was generally observed for two to three days toward the end of the clinical phase of the condition. The feces at this time varied in consistency usually being more fluid than normal. Excessive mucus in the feces was usually quite evident. Standing with their backs arched dorsally and frequent kicking at the abdomen, by many of the calves, indicated the presence of abdominal pain.



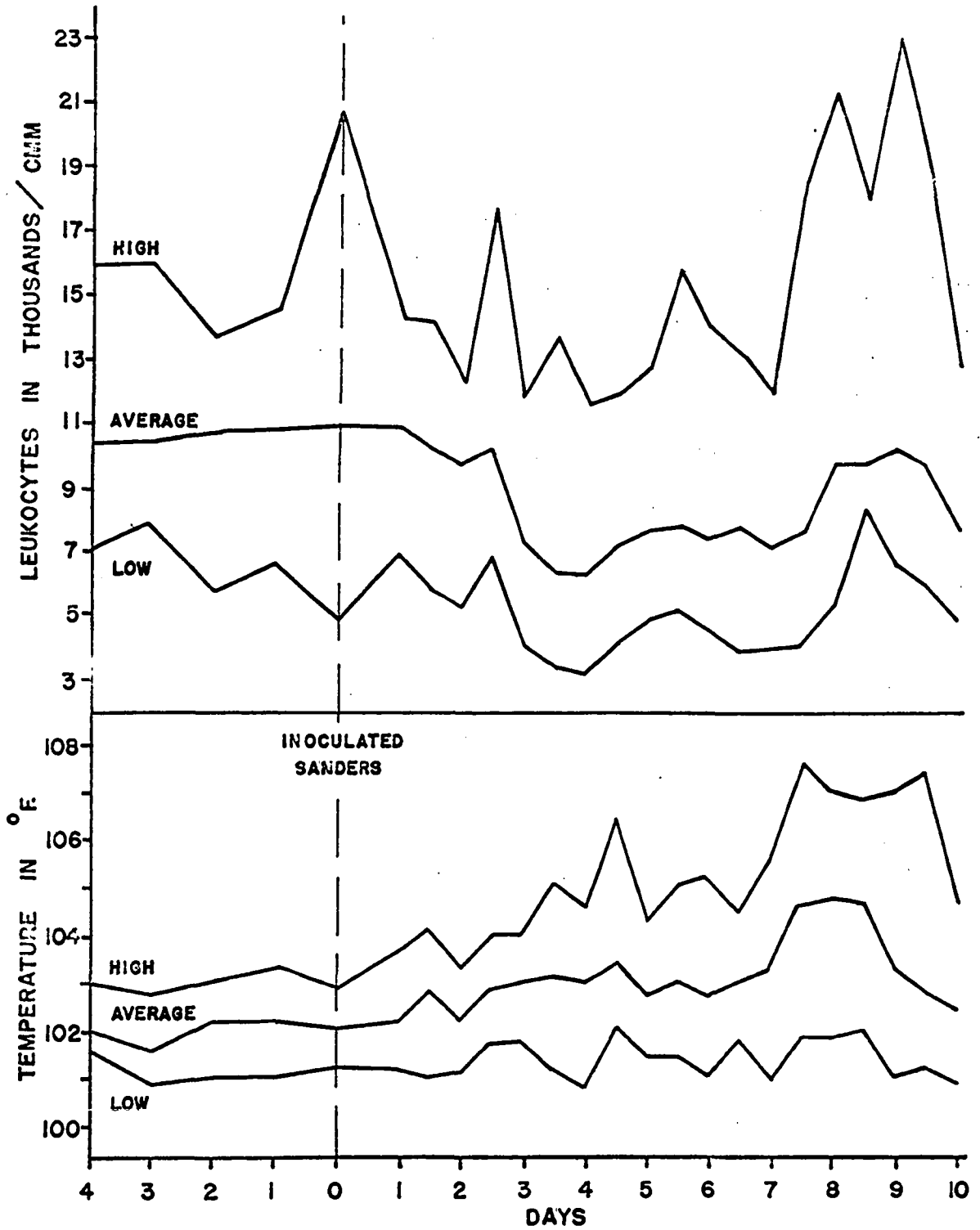


FIGURE I. LEUKOCYTE AND TEMPERATURE RESPONSE IN 22 CALVES INOCULATED WITH SANDERS AGENT. ONLY THE RANGE AND MEAN VALUES ARE GIVEN.

Erosions of the oral mucosa were seen in only a few calves. Infrequent, dry coughing was rarely noted during the clinical phase of the infection.

After the ninth or tenth day following inoculation the animal rapidly returned to apparently good health. Neither recurrence of infection nor chronic illness was observed.

#### Merrell and IVD 46 agents

Ten calves were inoculated with the Merrell agent and six with the IVD 46 agent. The reaction in these calves was not appreciably different from those infected with Sanders agent. It was observed, however, that the first temperature rise was usually more marked with these agents. Graphic representation of the thermal response to these agents is presented in Figures 2 and 3.

#### NADL-MD agent

The eight calves inoculated with this agent responded very similarly to those that had been inoculated with the Sanders agent. The only significant variation was that the first temperature rise came between the first and third day rather than between the third and fifth day. From the third to the sixth day the temperature gradually elevated and then rose sharply for a second peak on the seventh through the ninth day. These values are charted in Figure 4.

#### North Dakota (BMD) and Nebraska (C-1) agents

Fourteen calves were inoculated with the North Dakota (BMD) agent and thirteen with the Nebraska (C-1) agent. The clinical reactions elicited by these two agents were almost identical and were characterized by the following:

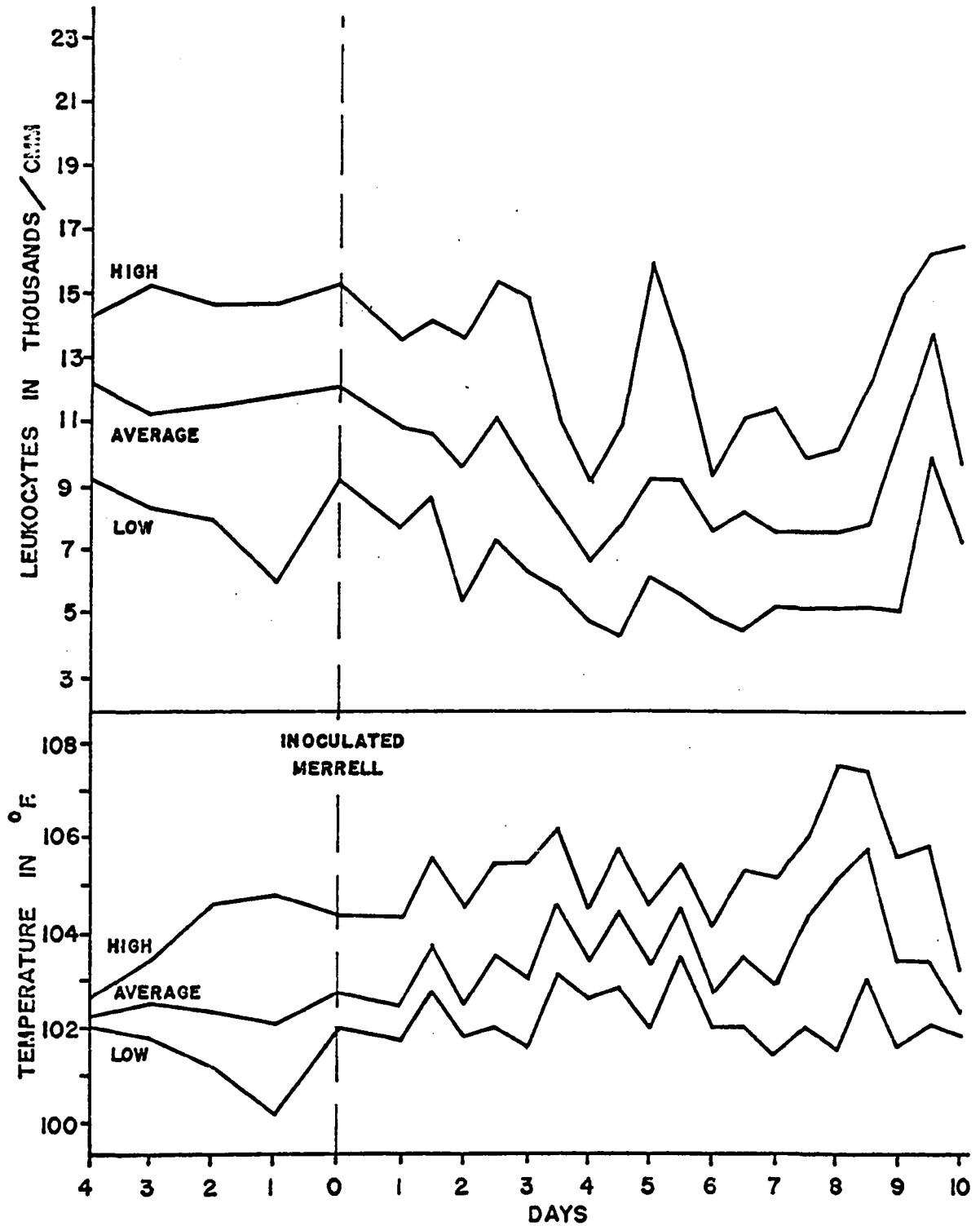
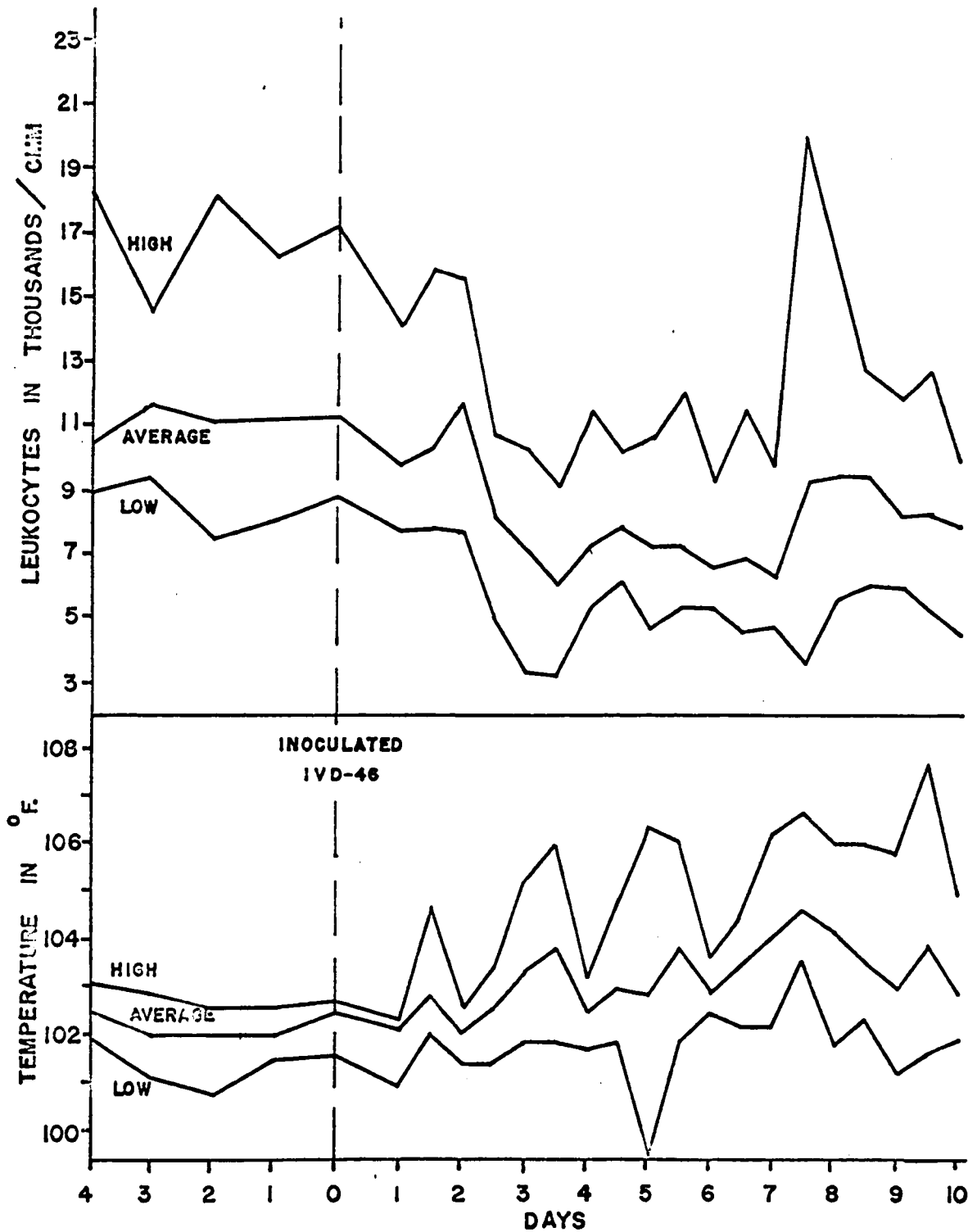


FIGURE 2. LEUKOCYTE AND TEMPERATURE RESPONSE IN 10 CALVES INOCULATED WITH MERRELL AGENT. ONLY THE RANGE AND MEAN VALUES ARE GIVEN.



**FIGURE 3. LEUKOCYTE AND TEMPERATURE RESPONSE IN 6 CALVES INOCULATED WITH IVD-46 AGENT. ONLY THE RANGE AND MEAN VALUES ARE GIVEN.**

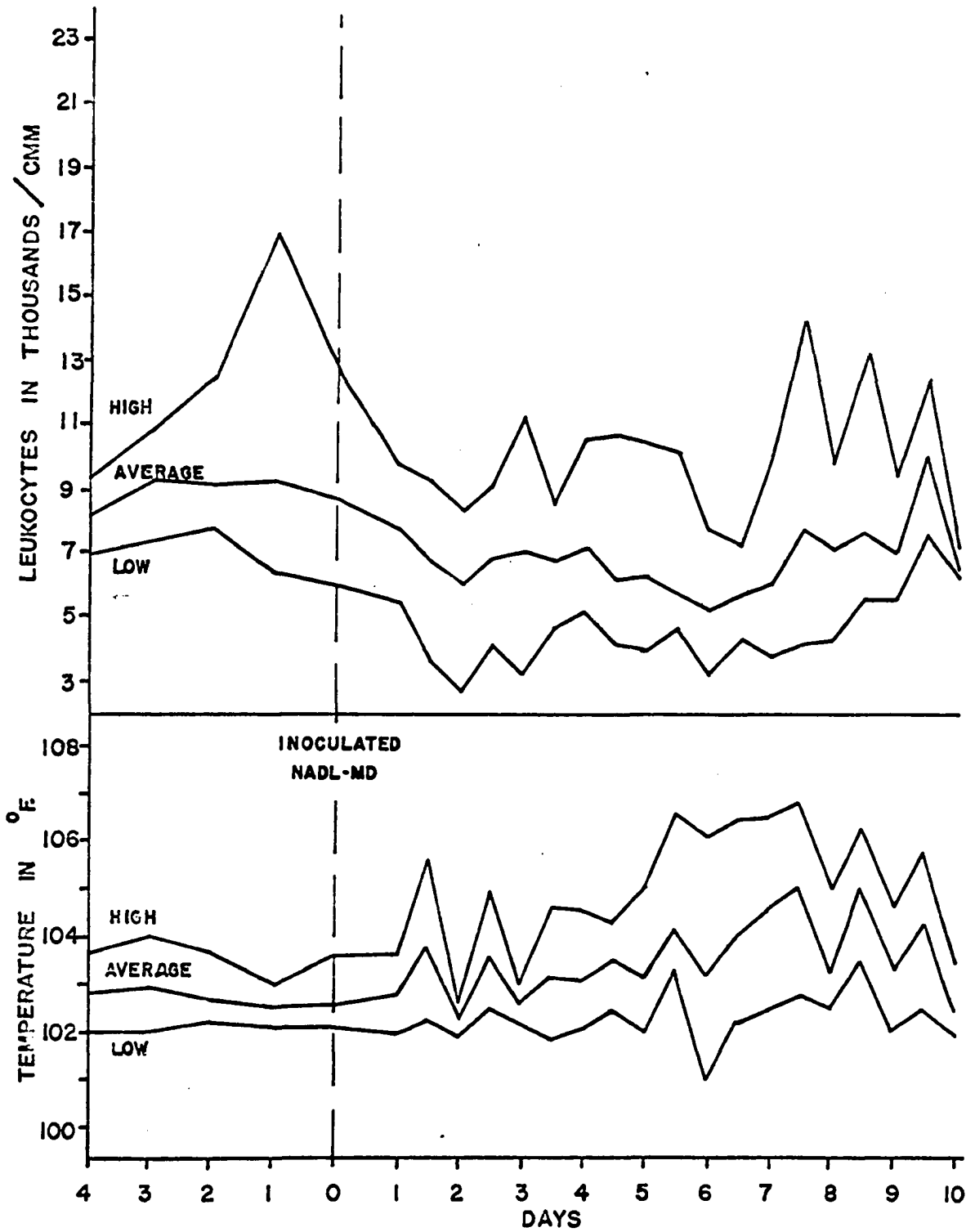


FIGURE 4. LEUKOCYTE AND TEMPERATURE RESPONSE IN 8 CALVES INOCULATED WITH NADL-MD AGENT. ONLY THE RANGE AND MEAN VALUES ARE GIVEN.

The temperature elevation was monophasic with its inception between the first and second day postinoculation and usually peaking at two to five degrees above the preinoculation level on the following day. This state persisted for approximately two days and then declined toward a more normal level which ensued between five and six days after inoculation as can be observed in Figures 5 and 6. During this period the calf was moderately depressed and consumed less feed. A noticeable mucous nasal discharge was also noted at this time. Frequently a diarrhea would develop toward the end of the febrile stage. This condition persisted for three to four days and longer in a few calves. Increased peristalsis of the intestinal tract was noted as the feces became more fluid than normal.

A dry, nonproductive cough was occasionally observed during the clinical phase of the condition.

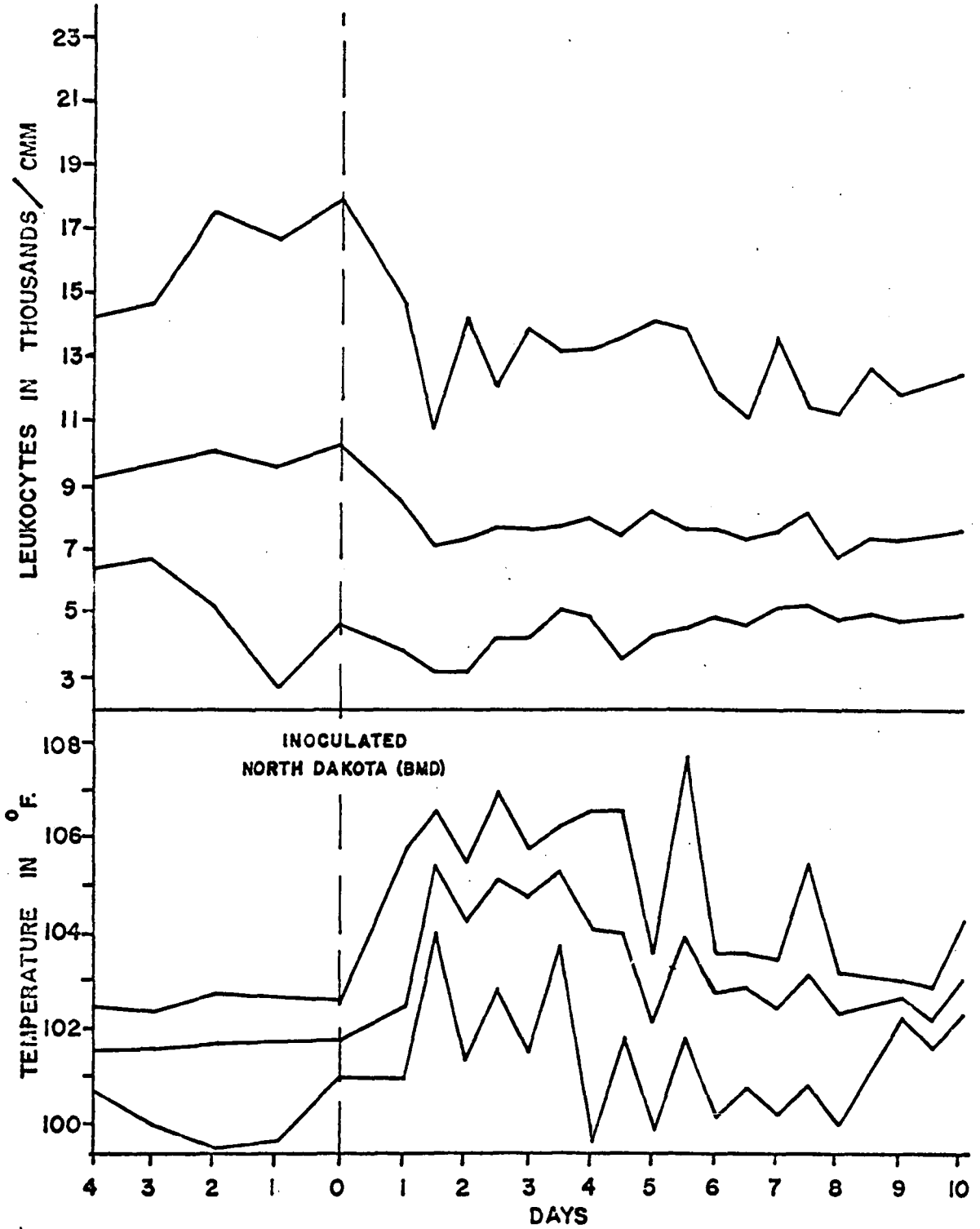
Erosions of the oral mucosa were not observed.

Following the cessation of the pyrexia and diarrhea, the calves rapidly returned to apparently good health.

#### IBR virus

Two calves were inoculated intranasally and one intravenously with the IBR virus. The response varied depending upon the route of administration. If it were given intravenously, the reaction was similar to that described for calves inoculated with either the Nebraska (C-1) or North Dakota (BMD) agents. After an intranasal inoculation the following response was observed:

The temperature began rising on the third day and reached its peak the following day at two to three degrees above the preinoculation



**FIGURE 5. LEUKOCYTE AND TEMPERATURE RESPONSE IN 14 CALVES INOCULATED WITH NORTH DAKOTA (BMD) AGENT. ONLY THE RANGE AND MEAN VALUES ARE GIVEN.**

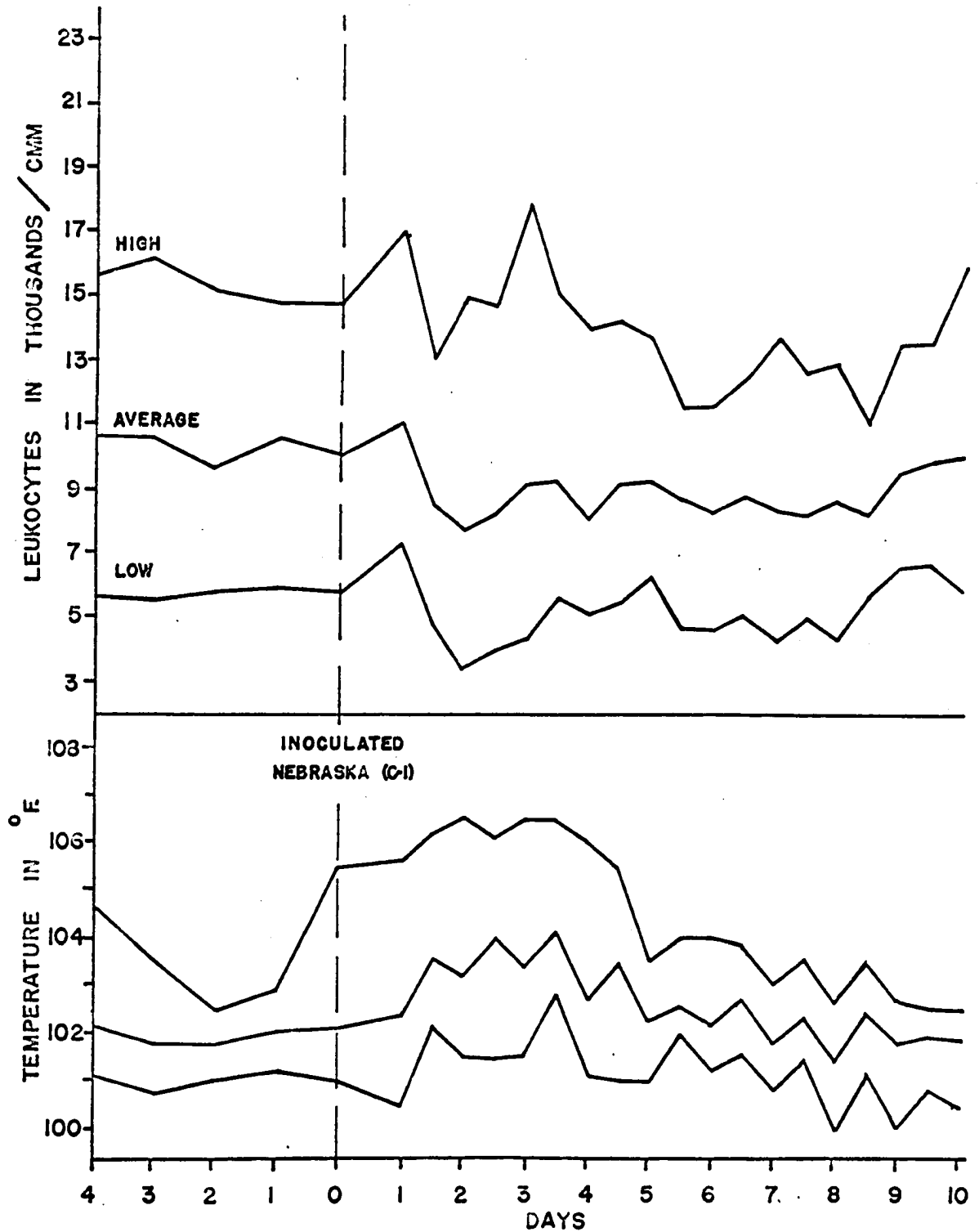


FIGURE 6. LEUKOCYTE AND TEMPERATURE RESPONSE IN 13 CALVES INOCULATED WITH NEBRASKA (C-1) AGENT. ONLY THE RANGE AND MEAN VALUES ARE GIVEN.



level. It dropped slightly but persisted near this level for the next four days and then decreased to almost normal levels. A marked mucous nasal discharge and serous lacrimation accompanied the pyrexia.

Breathing was dyspneic in one calf but was affected very slightly in the other. Both calves were depressed during the febrile stage of the infection. Coughing was not observed.

#### Combination of agents

Sixteen calves were used in this portion of the study. Two received a combination of Sanders and IVD 46 agents; two, Sanders and NADL-MD; two, Sanders and Nebraska (C-1); four, Sanders and North Dakota (BMD); two, Sanders, Merrell and IVD 46; and six, Sanders and Merrell. In general, when the Sanders, Merrell, NADL-MD or IVD 46 agents were used in various combinations, the response was only slightly varied from that produced by a single inoculation of any of these agents.

One notable exception was a trial using a combination of the Sanders and Merrell agents. In this experiment the first temperature elevation was quite marked reaching three and one-half degrees above the preinoculation level. After reaching this peak, it dropped slightly for one day and again climbed steadily the next few days until it peaked at four and one-half degrees above the norm on the seventh day. The calf was markedly depressed during the entire clinical phase of the condition. The depression was characterized by inappetence, lassitude, reluctance to move and gastro-intestinal distress as noted by the animal occasionally kicking at its abdomen. A severe watery diarrhea with a very fetid odor developed on the sixth day. The calf was euthanatized for pathologic study on the seventh day postinoculation.

The response in calves to combined inoculation of either the North Dakota (BMD) or the Nebraska (C-1) agents with the Sanders agent was variable depending on whether they were administered simultaneously or separately and especially which agent preceded the other by a time lapse of at least 24 hours. If the agents were given concurrently, the resulting response was not quite typical of either agent. In the four calves inoculated with a combination of the Sanders and North Dakota (BMD) agents the general pattern of the pyrexia was biphasic resembling an infection with the Sanders agent. The first peak, however, which occurred from the first through the fifth day, was more characteristic of the infection caused by the North Dakota (BMD) agent. The second temperature peak was also unusual in that it did not develop until the ninth day and persisted through the twelfth day. Although other responses were similar to what has been described for a single inoculation of either agent, they persisted longer than normally would be expected. Diarrhea was a prominent symptom of this infection. It was profuse and watery and persisted for several days. In one calf the diarrhea was still **persistent** at the time the calf was killed on the thirteenth day after inoculation.

When the agents were given several days apart, the response was more characteristic of a single administration of the initial inoculant. Two calves were inoculated with the Sanders and Nebraska agents in this manner. In one trial the Sanders agent was given at the peak of the clinical reaction following an initial inoculation with the Nebraska (C-1) agent. The response was typical of a single inoculation of the Nebraska (C-1) agent. The converse of this trial produced a response characteristic of a single administration of the Sanders agent.

## Hematologic Observations

Sanders agent

Twenty-two calves were used in this portion of the study. The total leukocyte count fell to approximately fifty per cent of the preinoculation level between the third and fourth day. It then rose to about sixty per cent of the norm and remained at this level until the seventh day. At that time the count usually returned to within the limits of the preinoculation level. Between the seventh and ninth day the leukocyte count frequently rose sharply to levels above the preinoculation standard and fell with the same rapidity again to the limits of the norm. These changes are shown graphically in Figure 1.

Evaluation of the differential leukocyte counts taken at the time of the most severe leukopenia revealed a decrease in total neutrophils of fifty-seven per cent and in total lymphocytes of forty-four per cent below the preinoculation level. Eosinophil, monocyte and basophil counts were not appreciably affected. These observations are summarized in Table 1. The sharp rise occurring between the seventh and eighth day was reflected in an increase in neutrophils.

Merrell and IVD 46 agents

Nine calves received the Merrell agent and six were inoculated with the IVD 46 agent. The general pattern of the total leukocyte counts was not appreciably different from those described for the Sanders agent. These changes are shown graphically for each agent in Figures 2 and 3.

In those calves infected with the Merrell agent, the changes in the differential leukocyte counts during the period of the most marked leukopenia were characterized by a decrease of thirty-nine per cent in

total lymphocytes below the preinoculation level and a forty-four per cent drop in total neutrophils. Other leukocyte numbers remained unchanged. The differential leukocyte counts for the IVD 46 infected calves revealed a fifty per cent decline in total lymphocytes and a forty-eight per cent decrease in total neutrophils below the preinoculation standard. Significant changes in the other leukocyte values were not observed. The changes in leukocyte values are summarized in Table 1.

#### NADL-MD agent

Six calves were inoculated with the NADL-MD agent. The total leukocyte count was erratic in its pattern but was generally observed to be significantly depressed by the second day after inoculation. Although it rose to more normal levels after this low, it tended to stay below preinoculation levels for several days. Between the fourth and sixth day the count often became depressed below the point observed on the second day. Following this period of depression the count rapidly returned to the limits of the preinoculation norm. A sharp rise above preinoculation levels was often observed between the sixth and tenth day. These changes are shown graphically in Figure 4.

The differential leukocyte counts made during the period of the greatest leukopenia indicated a drop in the total lymphocytes to thirty-nine per cent below the preinoculation level. A decrease of forty-one per cent was observed in the total neutrophil count. No appreciable change was noted in the other leukocyte numbers. Table 1 presents a summary of these changes in leukocyte values.

#### North Dakota (BMD) and Nebraska (C-1) agents

Eight calves were inoculated with the Nebraska (C-1) agent and

twelve with the North Dakota (BMD) agent. The total leukocyte count dropped about forty per cent below the preinoculation level by the second day after inoculation. The count rose to about twenty per cent of normal after this low and remained near this same level until the tenth day postinoculation when it gradually returned to more normal levels. These changes are graphically illustrated in Figures 5 and 6.

During the period of the most marked leukopenia, differential leukocyte counts made from calves infected with the North Dakota (BMD) agent revealed a decrease of forty-one per cent in total lymphocytes and forty-eight per cent in total neutrophils below the preinoculation readings. Similar counts made from calves infected with the Nebraska (C-1) agent disclosed a decrease of thirty-four per cent in total lymphocytes and sixty per cent in total neutrophils. Counts of other leukocytes were not significantly altered. Changes in leukocyte values are shown in summary form in Table 1.

#### IBR virus

Three calves were used in this phase of the study. Two were inoculated intranasally and one intravenously. Although the leukocyte response was too varied between the two intranasally infected calves to get an indication of a definite pattern, a leukopenia of approximately thirty per cent occurred between the second and fourth days. Differential leukocyte counts made at this time revealed a twenty-nine per cent decline in total lymphocytes and a forty-seven per cent decrease in total neutrophils. Changes were not noted in the counts of the other leukocytes.

The leukocyte response in the calf receiving the intravenous inoculation was quite similar to those described for calves inoculated with the

North Dakota (BMD) and Nebraska (C-1) agents. The leukocyte changes produced by the IBR virus are compared to those of the other agents in Table 1.

Combination of agents

The changes in the total leukocyte count in the two calves inoculated with a combination of the Sanders and IVD 46 agents were not appreciably different from those inoculated with either agent singly. This was also true of the two calves which received the combination of the Sanders and NADL-MD agents and six of the seven calves inoculated with combined Sanders and Merrell agents.

The differential counts in calves inoculated concurrently with Sanders and Merrell agents were little different from those resulting from single inoculations. This was not the case in calves inoculated with a combination of the Sanders and IVD 46 agents. In these calves a much greater decrease in lymphocytes than neutrophils occurred. One of the calves receiving the Sanders and Merrell agents developed a leukopenia of forty per cent on the third day after inoculation. The count remained near this depressed level until the calf was killed on the twelfth day postinoculation. The leukopenia of the first few days was characterized by a slightly greater decrease in lymphocytes than in neutrophils. The reverse was true of the last few days. A similar response was observed in the four calves receiving a combination of the Sanders and North Dakota (BMD) agents. Of the calves inoculated with sequential inoculations of the Sanders and Nebraska (C-1) agents, the calf inoculated initially with Sanders and three days later with Nebraska (C-1) agent responded similarly to calves receiving an inoculation of the Sanders

Table 1. Summary of changes in total leukocyte, lymphocyte and neutrophil counts.<sup>a</sup>

Agent	No. of Calves	Preinoculation <sup>b</sup>			Postinoculation <sup>c</sup>			Per cent Change		
		Total <sup>d</sup> Leuko-cytes	% <sup>e</sup> Lympho-cytes	% Neutro-phils	Total Leuko-cytes	% Lympho-cytes	% Neutro-phils	Total Leuko-cytes	Total Lympho-cytes	Total Neutro-phils
Sanders	22	10860	72	27	5560	78	20	-48	-44	-57
Merrell	9	12100	73	26	6300	77	22	-46	-39	-44
IVD 46	6	11000	76	23	5400	75	23	-50	-50	-48
Nebraska North Dakota	8	10830	72	28	6160	81	18	-43	-34	-60
NADL-MD	12	9450	74	25	5100	75	19	-44	-41	-48
IBR <sup>f</sup>	6	8500	71	28	4980	72	26	-40	-39	-41
IBR <sup>g</sup>	2	10300	60	36	7300	60	40	-29	-29	-47
Sanders + Merrell	1	11400	70	26	6100	69	31	-46	-48	-40
Sanders + North Dakota	7	10800	71	28	5800	72	27	-45	-44	-48
Sanders + IVD 46	4	9500	65	35	6540	75	25	-31	-17	-46
	2	10500	76	22	5700	67	32	-45	-53	-13

<sup>a</sup>Values are an average of the readings obtained from all calves infected with a given agent.

<sup>b</sup>Values are an average of the three days readings obtained just prior to inoculation.

<sup>c</sup>Prior to obtaining the average, values were taken at the point of greatest leukopenia for each calf.

<sup>d</sup>Total leukocytes in thousands per cmm.

<sup>e</sup>Since obvious changes were seen only in the lymphocyte and neutrophil counts, the values for other leukocytes are not included.

<sup>f</sup>IBR virus given intranasally.

<sup>g</sup>IBR virus given intravenously.

agent alone. The calf inoculated first with the Nebraska (C-1) agent and subsequently with Sanders agent developed a leukocytosis of fifty per cent on the second day after inoculation. The leukocytosis, which persisted for four days, was characterized by an increase in neutrophils. The changes in leukocyte values resulting from combined inoculations are presented in Table 1.

The packed cell volume and hemoglobin level were not appreciably affected by the infection resulting from the inoculation of any of the agents included in this study.

#### Gross Pathologic Observations

##### Sanders, Merrell, IVD 46 and NADL-MD agents

Four calves infected with Sanders agent and two each with the other three agents were used in this portion of the study. There was no appreciable difference in the pathologic response elicited by these agents. The characteristic lesions were as follows:

Small, linear areas of necrosis and erosion were seen in the epithelial lining of the esophagus in most of the calves infected with the IVD 46 and NADL-MD agents (Figure 7). Although they usually appeared throughout the length of the esophagus, they were more prominent and more severe in the posterior region.

Sloughing of the epithelium of the abomasum was frequently seen. These lesions were quite shallow and irregular in shape and more frequently found on the spiral folds. A mild to marked catarrhal enteritis was the most consistent finding. It was characterized by hyperemia, edema of the mucosa and gut wall and a catarrhal exudate in the lumen (Figure 8). The lesions were most severe in the jejunum. The Peyer's patches appeared




Figure 7. Small foci of necrosis in the esophageal mucosa.  
Pencil points to one small focus.

(C-1099 infected with IVD 46 agent)

Figure 8. Hyperemia and catarrhal inflammation of the small  
intestine.

(C-82 infected with NADL-MD agent)



swollen and markedly elevated above the intestinal surface, often with a distinct hyperemic border.

The mesenteric lymph nodes were slightly enlarged and edematous. Serous fluid readily flowed from their cut surfaces.

Edema was seen infrequently in the mesentery of the posterior portion of the ileum.

The cecum and colon were similarly but less involved. Occasionally shreds of a muco-fibrinous exudate were observed in the contents of the colon.

Other thoracic and abdominal viscera appeared to be visibly unaffected.

#### North Dakota (BMD) and Nebraska (C-1) agents

Two calves were used for each of the agents. In general, the pathologic response in calves inoculated with these two agents was similar to that described for the above agents (Figure 9). However, one additional lesion was invariably present. This consisted of marked multiple necrotic foci in the adrenal cortices (Figures 10 and 11). These foci measured between .5 and 2 mm and were scattered throughout the cortex of both glands.

It is emphasized that infection by the intravenous route did not produce either esophageal erosions or lesions of the respiratory tract. Lesions in other viscera were not grossly discernible.

#### IBR virus

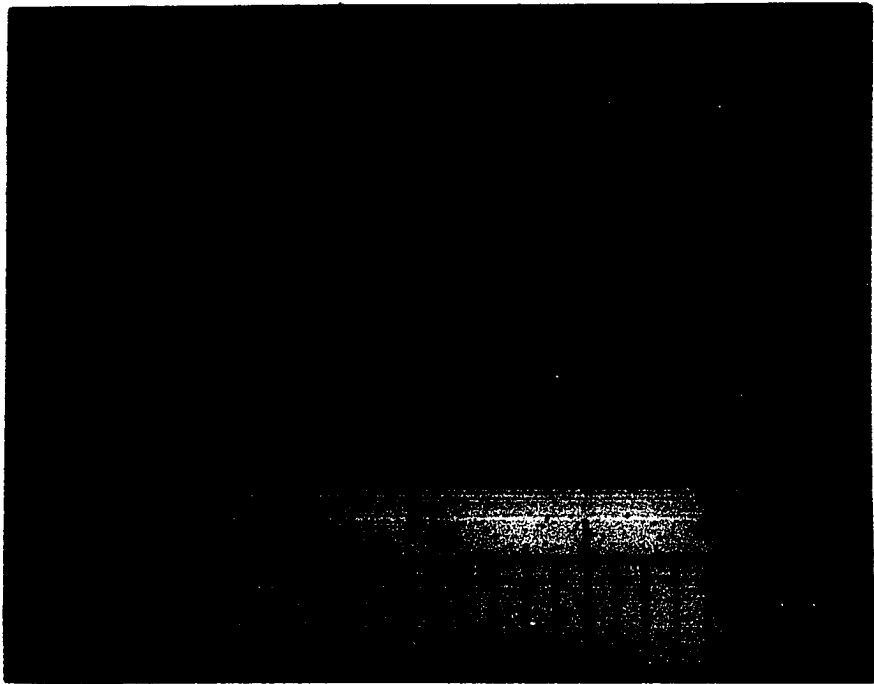
Three calves were used. Two had been inoculated intranasally and one intravenously. The lesions produced by this virus depended on the route of administration. If it were given intravenously, it produced

Figure 9. Hyperemia and catarrhal inflammation of the small intestine.

(C-1097 infected with North Dakota (BMD) agent)

Figure 10. Multiple foci of necrosis in the adrenal cortex.

(C-1097 infected with North Dakota (BMD) agent)



lesions very similar to those caused by an infection of North Dakota (BMD) and Nebraska (C-1) agents (Figures 9, 10 and 11). Intranasal inoculation produced lesions confined to the upper respiratory tract. These consisted primarily of a multiple focal fibrino-necrotic rhinitis and laryngitis.

#### Combined agents

Three calves infected with a combination of the Sanders and Merrell agents and one each with combinations of the Sanders agent with the IVD 46 and NADL-MD agents were killed for this part of the study. Three calves infected with Sanders and North Dakota (BMD) agents and two with Sanders and Nebraska (C-1) agents were euthanatized. If the Sanders agent were given concurrently with either the Merrell, IVD 46 or the NADL-MD agents, the pathologic response was generally no greater or different than would be expected from an inoculation of either agent by itself. One exception to this observation is noteworthy. In one trial of a combined inoculation of the Sanders and Merrell agents the response was very severe. The most marked lesions were in the Peyer's patches. They contained multiple fibrino-necrotic foci measuring from 2 to 10 mm in diameter (Figures 12 and 13). Some of the necrotic mucosa had sloughed leaving deep ulcers. Petechial to ecchymotic hemorrhage and fibrino-catarrhal exudation were quite marked in the mucosa covering the Peyer's patches. Similar, but remarkably fewer lesions were seen on the mucosa adjacent to the Peyer's patches. The intestinal wall was considerably thickened by edema.

The pathologic response in the three calves which received the combined Sanders and North Dakota (BMD) agents was more marked than the single administration of either agent. The most striking difference was the presence of erosions of the epithelium of the rumen. Erosions

Figure 11. A magnified view of Figure 10. Note the multiple necrotic foci. X 2.

(C-1097 infected with North Dakota (BMD) agent)

Figure 12. Multiple foci of necrosis in the lamina propria covering the Peyer's patches. An isolated Peyer's patch from the jejunum is present in the top section. The bottom section is a portion of the terminal ileum.

(C-1035 infected with a combination of Sanders and Merrell agents)







Figure 13. Terminal ileum with multiple foci of necrosis and fibrinous exudation.

(C-1035 infected with a combination of Sanders and Merrell agents)



were also present in the epithelium of the esophagus and omasum in one of the calves. In the esophagus, there were multiple small linear foci of necrosis measuring from 1 to 5 mm in length. They were present throughout the length of the esophagus. In the rumen and omasum the lesions were larger in diameter and more irregular in outline. Although appearing primarily on the pillars of the rumen, the erosions in the omasum were spread diffusely over the leaves.

The intestine was markedly hyperemic and contained an increased quantity of mucus. Peyer's patches were very prominent and hyperemic. In two calves there were numerous fibrino-catarrrhal plugs in many of the crypts of the colon.

Because of the lengthened observation period in the study of the Sanders and Nebraska (C-1) combination, the calves were not euthanatized until fourteen days after inoculation. By this time the only lesion resembling those characteristic of either syndrome was focal necrosis in the adrenal cortices.

#### Histologic Observations

##### Sanders agent

Lesions were not seen in the esophagus or rumen sections.

The only significant lesion observed in the abomasum was a mild hyperemia and edema in the lamina propria. The edema usually caused noticeable separation of the glands (Figures 14 and 15). Some loss of both chief and parietal cells was also commonly observed. The surface epithelium of the glands was frequently sloughed.



Lesions in the duodenum were quite mild and consisted primarily of hyperemia, edema and leukocytic infiltration of the lamina **propria**. The

Figure 14. Edema of the lamina propria of the abomasum. Some loss of both parietal and chief cells is evident. X 160. Hematoxylin and eosin stain.

(C-82 infected with NADL-MD agent)

Figure 15. Section of abomasum from an apparently healthy calf. Compare with Figure 14. X 160. Hematoxylin and eosin stain.

(MD-189 control calf)



hyperemia was most pronounced at the tips of the villi. A mild to moderate leukocytic infiltration was invariably observed. Although eosinophils were the most prevalent cell, macrophages and lymphocytes also contributed to the infiltrate (Figures 16 and 17). A frequent observation was caseous necrosis of the tips of the villi (Figures 18 and 19). This lesion was more severe and more commonly seen in the duodenum than in the remainder of the small intestine.

The lesions in the jejunum and ileum were similar but generally more severe than those in the duodenum (Figures 16 through 19). In addition, depletion of lymphocytes in Peyer's patches was invariably observed (Figure 20). This depletion was more severe in the ileal patches than in those of the jejunum. Infiltration of macrophages into the Peyer's patches accompanied the depletion (Figures 21, 24 and 26). Necrosis of lymphoid tissue was commonly observed. Macrophages containing great quantities of cellular debris in their cytoplasm were prominent in the affected patches (Figure 21). More advanced necrosis was evidenced by an almost complete lack of cellular detail and the presence of a proteinaceous, fibrinoid residue in the nodule (Figures 20 and 22 through 26). Not all nodules within a patch were affected equally (Figure 20). There were marked hyperemia and edema of the submucosa immediately below the affected Peyer's patch. Lymph vessels were distended with highly proteinaceous lymph and many leukocytes. Leukocytes also infiltrated into the edematous submucosa (Figure 27). The edema extended between the individual nodules of the Peyer's patch making them appear to be separated (Figure 22). Cystic glands containing cellular debris and mucus were occasionally seen (Figures 29 and 30). Lesions in the colon resembled those observed in the small intestine but were not as pronounced (Figure 28).

Figure 16. Hyperemia and leukocytic infiltration of the lamina propria of the jejunum. Note that the predominant cell in the infiltrate is the eosinophil. X 400. Hematoxylin and eosin stain.

(C-88 infected with NADL-MD agent)

Figure 17. Section of jejunum from an apparently healthy calf. X 400. Hematoxylin and eosin stain.

(MD 180-5 control calf)






Figure 18. Caseous necrosis of the tips of the villi in the duodenum. Note the leukocytic infiltration of the lamina propria. X 160. Hematoxylin and eosin stain.

(C-1097 infected with North Dakota (BMD) agent)

Figure 19. Caseous necrosis of the tips of the villi in the jejunum. Leukocytic infiltration of the lamina propria is also prominent. X 160. Hematoxylin and eosin stain.

(C-1070 infected with a combination of Sanders and IVD 46 agents)





Figure 20. Lymphoid exhaustion of a nodule of a Peyer's patch in the jejunum. Edema and fibrinoid residue can also be seen. An adjacent nodule is little affected. X 160. Hematoxylin and eosin stain.

(C-1142 infected with a combination of Sanders and Merrell agents)

Figure 21. Peyer's patch from the ileum of a calf killed four days after infection. Macrophages distended with cellular debris are evident throughout the nodule. X 400. Hematoxylin and eosin stain.

(C-127 infected with Sanders agent)




Figure 22. Marked depletion of lymphocytes from an ileal Peyer's patch. Observe the edema between the individual nodules. X 60. Hematoxylin and eosin stain.

(C-88 infected with NADL-MD agent)




Figure 23. Higher magnification of Figure 22. Necrotic cellular debris is evident in the center of the nodule. An eosinophilic, fibrinoid residue is also prominent throughout the nodule. X 160. Hematoxylin and eosin stain.

(C-88 infected with NADL-MD agent)

Figure 24. Higher magnification of Figure 23. Necrotic cellular debris and fibrinoid residue are quite evident. The presence of large numbers of macrophages are also noted. X 400. Hematoxylin and eosin stain.

(C-88 infected with NADL-MD agent)







Figure 25. Depletion of lymphocytes in lymphoid nodules of a Peyer's patch of the ileum. Note the central areas of eosinophilic, fibrinoid residue. X 160. Hematoxylin and eosin stain.

(C-1035 infected with a combination of Sanders and Merrell agents)

Figure 26. Higher magnification of Figure 25. Macrophages and eosinophilic, fibrinoid residue are plainly evident. X 400. Hematoxylin and eosin stain.

(C-1035 infected with a combination of Sanders and Merrell agents)




Figure 27. Submucosal edema beneath a Peyer's patch of the jejunum. Note the presence of neutrophils in the exudate and in the lymph channels. A depleted lymph nodule is at the right. X 160. Hematoxylin and eosin stain.

(C-1142 infected with a combination of Sanders and Merrell agents)

Figure 28. Lymph nodule from the colon. Note depletion of lymphocytes, infiltration of macrophages and degenerating erythrocytes. X 400. Hematoxylin and eosin stain.

(C-1035 infected with a combination of Sanders and Merrell agents)

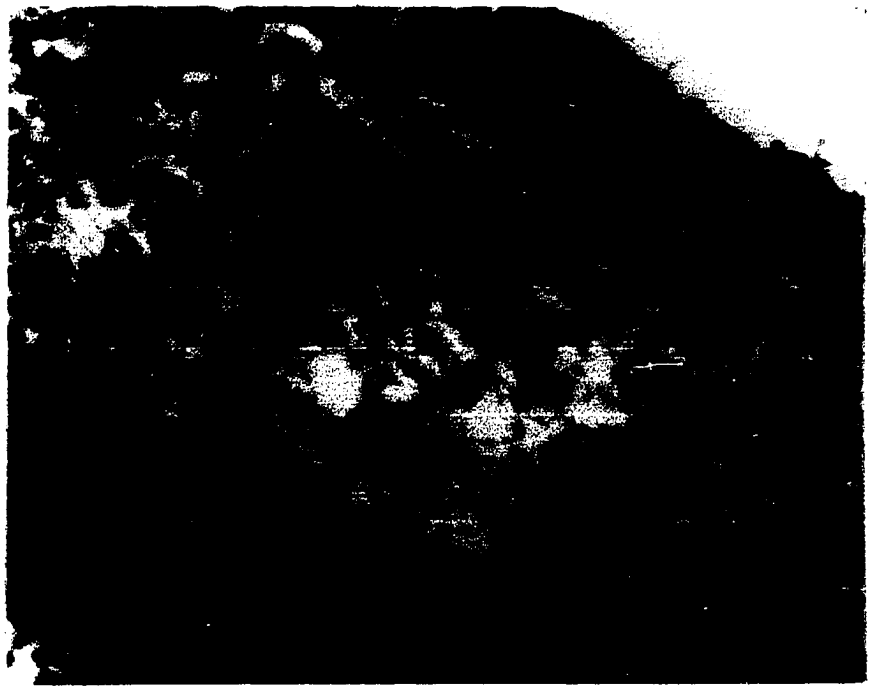



Figure 29. Cystic distention of a gland in the mucosa of the ileum containing mucus and cellular debris. Note the depletion of lymphocytes from the adjacent lymph nodule. X 160. Hematoxylin and eosin stain.

(C-88 infected with NADL-MD agent)

Figure 30. Section of the ileum containing a cystic gland in the mucosa. The contents of the cyst consists mostly of macrophages and cellular debris. X 400. Hematoxylin and eosin stain.

(C-1088 infected with a combination of Sanders and North Dakota (BMD) agents)



Multiple, minute foci of necrosis were observed throughout the liver (Figure 31). These foci usually contained from three to twelve leukocytes (Figures 31 and 32). Depending on the age of the lesion, neutrophils or lymphocytes predominated in these foci. Mild infiltration of the portal triads by lymphocytes was also observed (Figure 33).

Cloudy swelling of the tubular epithelium and accumulation of hyaline droplets in the tubules and Bowman's capsule were a common observation in the sections of the kidneys.

Mild to moderate depletion of lymphocytes in the germinal centers was the most frequent observation in the mesenteric lymph node sections (Figures 34, 35, and 36). The central portion of these centers was the most severely involved, often being completely devoid of lymphocytes (Figure 35). Necrosis of these areas was evidenced by the presence of a proteinaceous, fibrinoid residue and macrophages containing cellular debris (Figures 35 and 36). Hyperemia and edema particularly in the subcapsular spaces were frequently observed. Neutrophils in considerable numbers were occasionally seen infiltrating into the subcapsular space and/or the medulla of the node (Figure 37). Small, spherical hyaline bodies as described by Trapp (1960) were rarely seen in the germinal centers (Figure 36).

A mild lymphoid depletion of the Malpighian corpuscles was present in the spleen sections (Figures 38, 39 and 40). Evidence of necrosis of these centers was rarely seen. Pericorpuscular accumulation of neutrophils was a common observation (Figures 40 and 41). These cells often formed a complete cuff around the Malpighian corpuscles. In some cases the accumulation was so marked that it approached the consistency of a

Figure 31. Multiple microfoci of necrosis with leukocytic infiltration in the liver. X 160. Hematoxylin and eosin stain.

(C-1058 infected with Sanders agent)

Figure 32. Intralobular microfoci of hepatic necrosis with leukocytic invasion. Note that the neutrophils are predominant in these areas. X 400. Hematoxylin and eosin stain.

(C-1058 infected with Sanders agent)







Figure 33. Mild infiltration of lymphocytes into portal triads of the liver. X 160. Hematoxylin and eosin stain.

(C-1075 infected with Sanders agent)




Figure 34. Mesenteric lymph node with moderate lymphocytic depletion of the germinal centers. Note the eosinophilic, fibrinoid residue in these depleted centers. X 160. Hematoxylin and eosin stain.

(C-1058 - infected with Sanders agent)

Figure 35. Marked depletion of lymphocytes and accumulation of an eosinophilic, fibrinoid residue in the germinal center of a mesenteric lymph node. Edema is also evident. X 160. Hematoxylin and eosin stain.

(C-1142 infected with a combination of Sanders and Merrell agents)



Figure 36. Lymphoid depletion and fibrinoid residue in a germinal center of a mesenteric lymph node. Also to be seen are hyaline bodies of unknown origin and significance. X 400. Hematoxylin and eosin stain.

(C-1035 infected with a combination of Sanders and Merrell agents)

Figure 37. Subcapsular area of a mesenteric lymph node. Note the accumulation of neutrophils in the subcapsular sinus. X 400. Hematoxylin and eosin stain.

(C-1035 infected with a combination of Sanders and Merrell agents)




Figure 38. Section of spleen from an apparently healthy calf. A Malpighian corpuscle is in the center of the picture. Compare with Figure 39. X 160. Hematoxylin and eosin stain.

(MD-180 control calf)

Figure 39. A moderately depleted Malpighian corpuscle from a section of spleen. X 160. Hematoxylin and eosin stain.

(C-1142 infected with a combination of Sanders and Merrell agents)







Figure 40. A moderately depleted Malpighian corpuscle in the spleen. Pericorpuscular accumulation of neutrophils and pigment are also present. X 400. Hematoxylin and eosin stain.

(C-1142 infected with a combination of Sanders and Merrell agents)

Figure 41. Marked accumulation of neutrophils in the pericorpuscular area of a Malpighian corpuscle. X 400. Hematoxylin and eosin stain.

(C-1142 infected with a combination of Sanders and Merrell agents)



purulent exudate (Figure 41). Heavy accumulations of pigment were also present (Figure 40). Using Gormori's stain for iron, this pigment was found to contain no free iron (Figures 42 and 43).

A patchy, or rarely diffuse, depletion of thymocytes was observed in the sections of the thymus gland (Figure 44). Hyperemia and edema were infrequently seen.

Lesions were not visible in the adrenal gland.

Inclusion bodies were not observed in any of the sections.

#### Merrell, IVD 46 and NADL-MD agents

The histopathologic evaluation of sections taken from calves infected with these agents revealed slight variation from the lesions described for the calves infected with the Sanders agent. These variations were as follows:

Both the IVD 46 and NADL-MD agents frequently produced foci of necrosis in the stratified squamous epithelium of the esophagus and rumen. These lesions were initiated as very small areas of hypertrophy and hyperplasia. Subsequent changes were hydropic degeneration and death (Figures 45 and 47). The lesions spread from these small foci into other layers of the epithelium. Only rarely did they extend into the lamina propria. As the cells became necrotic, a pustule-like structure filled with cellular debris, leukocytes and proteinaceous fluid was formed (Figures 46 and 48). Migration of neutrophils through the epithelium into the site of necrosis was usually evident. Rupture of these pustules produced erosions. Accompanying the necrosis was a moderate infiltration of the submucosa and adjacent epithelium by leukocytes, predominantly neutrophils. Hyperemia and mild edema were also

Figure 42. Section from spleen from an apparently healthy calf. Free iron around the periphery of the Malpighian corpuscle stains blue. X 160. Gomori's iron stain counterstained with Kernechtrot.

(MD-189 control calf)

Figure 43. Accumulation of pigment around a Malpighian corpuscle in a calf infected with Sanders agent. Free iron is visible only at the center of the corpuscle. Compare with Figure 42. X 160. Gomori's iron stain counterstained with Kernechtrot.

(C-1142 infected with a combination of Sanders and Merrell agents)





Figure 44. Moderate depletion of thymocytes from the thymus gland.  
X 160. Hematoxylin and eosin stain.

(C-1118 infected with a combination of Sanders and  
Merrell agents)

Figure 45. Focal areas of necrosis in the stratum corneum of the  
esophageal epithelium. X 400. Hematoxylin and eosin  
stain.

(C-1099 infected with IVD 46 agent)






Figure 46. Focal areas of necrosis and pustule formation in the epithelium of the esophageal mucosa. This is a later stage than Figure 45. Note that the lesion has spread into the stratum spinosum and has stimulated a neutrophilic infiltration. X 400. Hematoxylin and eosin stain.

(C-1099 infected with IVD 46 agent)

Figure 47. Focus of necrosis in the stratum corneum of the rumen epithelium. Compare with Figure 45. X 400 Hematoxylin and eosin stain.

(C-1099 infected with IVD 46 agent)





Figure 48. Focal areas of necrosis and pustule formation in the rumen epithelium. The picture is from the same section as Figure 47. The break in the epithelium is an artifact. X 160. Hematoxylin and eosin stain.

(C-1099 infected with IVD 46 agent)

Figure 49. Focal caseous necrosis in the zona fasciculata of the adrenal cortex. Section was taken seven days after inoculation. X 60. Hematoxylin and eosin stain.

(C-27 infected with Nebraska (C-1) agent)



evident in the submucosa.

North Dakota (BMD) and Nebraska (C-1) agents

Lesions in the esophagus and rumen were not observed in sections taken from calves infected with these agents.

Mild hyperemia and edema were observed in the lamina propria of the abomasum. Some loss of parietal and chief cells was evident.

The lesions in the small intestine consisted of hyperemia, edema and a mild to moderate infiltration of lymphocytes into the lamina propria. Eosinophils and macrophages also contributed to the infiltrate. Occasionally such infiltrations were so marked that they induced atrophy of adjacent intestinal glands. Caseous necrosis of the tips of the villi was frequently observed in all areas of the small intestine (Figure 18). Although mild lymphoid depletion of the Peyer's patches was observed, there was no evidence of necrosis in these areas.

Lesions in the colon were similar to those in the small intestine but less pronounced.

Mild hyperemia, edema and very mild lymphoid depletion of germinal centers characterized the reaction in the mesenteric lymph nodes.

Other than occasional accumulation of neutrophils around a Malpighian corpuscle and very slight lymphoid depletion, the spleen was not remarkably affected.

Little or no depletion of thymocytes was noted in the thymus gland.

The most remarkable lesion occurring as the result of infection from these two agents was necrosis of the adrenal cortex. Foci of caseous necrosis restricted principally to the zona fasciculata were scattered throughout the cortex of the gland (Figure 49). Although there was

variation in the size of the lesions, they were consistently spherical in shape indicating radial spread from an infected focus. The largest areas extended between the inner and outer limits of the cortex. Necrosis appeared to be preceded by a marked hypertrophy of the involved adrenal cells. Small areas of hemorrhage and mild infiltration of neutrophils and lymphocytes usually accompanied the necrosis. As the lesion progressed, calcification of the necrotic tissue was evident (Figure 50). Regeneration of the damaged cortex was well underway by the thirteenth day after inoculation. At this time, many young cortical epithelial cells with hyperchromatic nuclei and scant cytoplasm were observed at the base of the zona fasciculata and throughout the reticularis (Figure 51).

Lesions in the liver were similar but generally more extensive and severe than those described for the Sanders agent (Figures 52, 53 and 54).

The lesions in the kidneys resembled those observed in sections from calves infected with the Sanders agent.

#### IBR virus

As with the clinical response, the histologic lesions varied with the route by which this agent was administered. If the agent were given intravenously the lesions were identical with those described for the North Dakota (BMD) and Nebraska (C-1) agents. When it was given intranasally the lesions were restricted primarily to the upper respiratory epithelium. Necrosis and sloughing of the nasal epithelial lining, leukocytic infiltration of the subepithelial tissue and hydropic degeneration of the cells of the subepithelial glands characterized these lesions. Occasionally small focal hemorrhages were observed in the lamina propria.

Figure 50. Focal caseous necrosis of the adrenal cortex. Yellow-brown staining material is calcium which indicates calcification of the necrotic tissue. X 160. Von Kossa's stain for calcium salts counterstained with Kernechtrot.

(C-184 infected with a combination of Sanders and North Dakota (BMD) agents)

Figure 51. An area of cortical regeneration at the base of the zona fasciculata below an area of necrosis. Note the irregularly polyhedral cells with hyperchromatic nuclei and scant cytoplasm. These are believed to be regenerating cortical cells. X 400. Hematoxylin and eosin stain.

(C-184 infected with a combination of Sanders and North Dakota (BMD) agents)







Figure 52. Focal hepatic necrosis with leukocytic infiltration.  
X 160. Hematoxylin and eosin stain.

(C-1097 infected with North Dakota (BMD) agent)

Figure 53. Higher magnification of Figure 52. The predominant  
leukocytes are lymphocytes. X 400. Hematoxylin and  
eosin stain.

(C-1097 infected with North Dakota (BMD) agent)






Figure 54. Fibrino-necrotic enteritis involving the lamina propria over a Peyer's patch in the jejunum. X 160. Hematoxylin and eosin stain.

(C-1035 infected with a combination of Sanders and Merrell agents)



The cellular infiltrate consisted of neutrophils, lymphocytes and macrophages. In early lesions hydropic degeneration of the epithelial lining cells was also observed. There were no inclusion bodies seen.

#### Combination of agents

In general when the Sanders agent was combined with either the IVD 46, Merrell or NADL-MD agents the histopathologic lesions were not significantly different from those seen in the single inoculations of any of the agents. The one exception referred to in other sections also appears here. One trial of combined Sanders and Merrell agents produced lesions that were classified microscopically as severe. The pattern of involvement, however, was little varied from that described for either agent singly. An additional observation was the presence of considerable necrosis of the lamina propria and a heavy fibrinous exudate on the epithelial surface above the Peyer's patches (Figure 54).

Since the calves inoculated with the combined Sanders and Nebraska (C-1) agents were not killed until two weeks after the initial inoculation, significant histologic lesions other than focal necrosis of the adrenal cortices were not observed.

The combination of the Sanders and North Dakota (BMD) agents produced moderate to marked histologic changes. Some lesions were characteristic of those produced when the agents were used alone. Others were different and had not been observed in sections from animals in which either agent was given by itself. Those lesions characteristic of the Sanders agent were the depletion and necrosis of lymphoid tissue in the Peyer's patches and germinal centers of the mesenteric lymph nodes. The lesion that characterized the activity of the North Dakota (BMD)

agent was focal necrosis of the zona fasciculata of the adrenal cortex. The lesions that had not been observed in animals affected singly by either agent were multiple focal areas of hydropic degeneration and necrosis of cells in the stratified squamous epithelium of the esophagus, rumen and omasum. These lesions were similar but, as a rule, more severe than those described in calves infected with the IVD 46 and NADL-MD agents.

The rumen epithelium was the most consistently and severely involved tissue. The lesions appeared to start as small foci of hydropic degeneration of cells in the stratum cylindricum or more commonly the stratum spinosum (Figure 55). Death of these cells was followed by cell rupture and coalescence of the hydropic fluid to form small vesicles. These vesicles progressed rapidly to pustules as neutrophils invaded the necrotic area (Figures 56, 59 and 60). After extending to the surface, the pustule ruptured. The resulting epithelial defect was filled with fibrin, neutrophils and necrotic cellular debris (Figure 57). It was interesting to note that even in the most severely affected areas the necrosis did not extend into the lamina propria. In these areas the stratum cylindricum was observed to be only a single cell in thickness but markedly stretched (Figure 57). Hyperemia and neutrophilic infiltration were prominent in the adjacent lamina propria (Figure 58).

Marked cystic degeneration of crypts of the colon was also seen in two calves. These cysts contained mucus and cellular debris (Figures 61 and 62).

#### Immunologic Observations

Fifty calves were used in this study. All calves initially inoculated with either the Sanders, Merrell, IVD 46 or NADL-MD agents were later

Figure 55. Hydropic degeneration of epithelial cells of the rumen pillar. Note the various stages of degeneration from cytoplasmic vacuolation to complete dissolution of the cell. Microvesicles are also evident. X 400. Hematoxylin and eosin stain.

(C-194 infected with a combination of Sanders and North Dakota (BMD) agents)

Figure 56. Pustule formation in necrotic area of the rumen epithelium. The picture is from the same section as Figure 55. X 400. Hematoxylin and eosin stain.

(C-194 infected with a combination of Sanders and North Dakota (BMD) agents)





Figure 57. Focal necrosis of the rumen epithelium. Note the exudate which contains neutrophils, fibrin and necrotic cellular debris. The intact, but markedly stretched, stratum cylindricum can also be seen. The picture was taken from the same section as Figure 56. X 160. Hematoxylin and eosin stain.

(C-194 infected with a combination of Sanders and North Dakota (BMD) agents)

Figure 58. Another view of the section shown in Figure 57. The subepithelial inflammatory reaction consists primarily of hyperemia and neutrophilic invasion. X 400. Hematoxylin and eosin stain.

(C-194 infected with a combination of Sanders and North Dakota (BMD) agents)


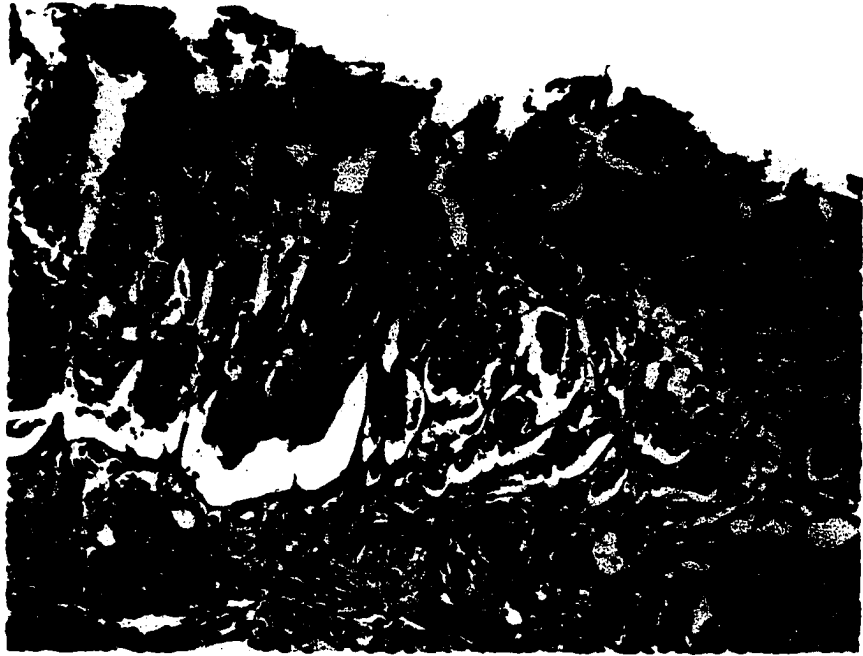


Figure 59. Focal necrosis and pustule formation in the epithelium of the omasum. X 60. Hematoxylin and eosin stain.

(C-1088 infected with a combination of Sanders and North Dakota (BMD) agents)

Figure 60. Higher magnification of Figure 59. Note that the pustule contains primarily degenerating epithelial cells, neutrophils and cellular debris. X 160. Hematoxylin and eosin stain.

(C-1088 infected with a combination of Sanders and North Dakota (BMD) agents)




Figure 61. Cystic degeneration of the glandular crypts of the mucosa of the colon. Note the great quantity of mucus in the submucosal glandular diverticulum. X 60. Hematoxylin and eosin stain.

(C-184 infected with a combination of Sanders and North Dakota (BMD) agents)

Figure 62. An area similar to Figure 61. The mucus stains red. X 60. Mayer's mucicarmine stain counterstained with metanil yellow.

(C-184 infected with a combination of Sanders and North Dakota (BMD) agents)



shown to be immune when challenged by any one of the other agents.

Occasionally a moderate temperature rise and leukopenia occurred between the seventh and ninth day following the challenge. The calves did not appear sick, however.

All calves inoculated by either the North Dakota (BMD) or Nebraska (C-1) agent and later challenged by the other agent were shown to be immune to the challenge.

Evidence of immunity was not apparent when calves initially inoculated with either the Sanders, Merrell, IVD 46 or NADL-MD agent were challenged with either the North Dakota (BMD) or Nebraska (C-1) agents. The converse of the experiment produced similar results. Each challenging agent produced a response typical of an initial inoculation with that agent.

Only one trial was performed with IBR virus. An initial inoculation of Sanders agent was followed in three weeks by an intravenous inoculation of the IBR virus. The response was typical of that expected from an initial inoculation of either the North Dakota (BMD) or Nebraska (C-1) agents.

## DISCUSSION

## Infective Agents

The mucosal disease and viral diarrhea agents used in this study were chosen because they produced a readily recognizable clinical syndrome in calves. This was necessary in order to determine whether cross immunity was responsible for the lack of a clinical response when a heterologous challenge was made. The Oregon C24V and C80K agents (Gillespie et al., 1960 and 1961) were originally included in this study but because of their inability to consistently elicit a recognizable clinical reaction in calves, they were discarded. Limited work with these agents indicated an immunologic relationship to the Sanders agent but none with the North Dakota (BMD) and Nebraska (C-1) agents.

The IBR virus studies were limited because this agent was not initially included in the study. It was only near the termination of this investigation that the North Dakota (BMD) and Nebraska (C-1) agents were found to be strains of the IBR virus. The IBR virus was used primarily to determine if the intravenous route of inoculation altered the clinical syndrome and lesions that would normally be expected when a known virulent strain of the virus was given by other routes.

The New York strain 1 of virus diarrhea was not included in the study because the work of Gillespie and Baker (1959) had shown that this agent was immunologically related to the Indiana 46 strain. The Indiana strain was available and was therefore used instead of the New York strain.

Although the Sanders, Merrell and IVD 46 agents will grow in cell cultures, evidence of their presence is not readily discernible. For



this reason, infective defibrinated blood was used as the source of inoculum for these agents.

#### Clinical and Hematologic Responses

The clinical and hematologic responses produced by the inoculation of the Sanders, Merrell, IVD 46 and NADL-MD agents were quite similar. The reaction was characterized by a diphasic temperature elevation with peaks usually recorded on the third and seventh days postinoculation.

A leukopenia, which was generally most pronounced on the third day after inoculation, was observed in the interval between the temperature elevations. A rise in the leukocyte levels, often quite marked, coincided with the end of the febrile period. The differential leukocyte counts taken at the time of the most severe leukopenia revealed little difference between the total neutrophils and total lymphocytes in their per cent of change. There was a slight tendency toward a more marked decrease in total neutrophils. This does not agree with the findings of Tyler (1960). In his work with the Merrell agent he reported a decidedly greater decrease (33%) in lymphocytes than in neutrophils. Trapp (1960) also reported an absolute as well as relative lymphopenia during the leukopenia of field cases of mucosal disease. Pritchard et al. (1954), however, reported a relative lymphocytosis during the leukopenic phase of field cases of virus diarrhea in Indiana cattle. Carlson et al. (1957) reported similar findings in cases of experimental virus diarrhea. Studies of the differential counts for the other agents have not been reported. Changes in the differential leukocyte pattern does not appear well characterized for this group of agents.

The signs of the mucous discharge, lacrimation and anorexia usually paralleled the periods of the temperature elevation. Diarrhea was consistently seen during or following the last febrile phase. These observations correspond with what has been described for these agents by other workers.

Chronic cases or recurrent infections as observed by Carlson et al. (1957) in several cases of experimental virus diarrhea were not observed in this study.

The earlier onset of symptoms and more rapid course of the reaction in calves inoculated with the NADL-MD agent are attributed to the fact that infective cell culture was used as the inoculum. The virus titer of such material is considerably greater than defibrinated blood.

The clinical and hematologic responses produced by the North Dakota (BMD) and the Nebraska (C-1) agent were very similar. The temperature rise was monophasic and usually extended from the second through the sixth day postinoculation. During this period the calves were depressed, off feed and developed a serous to mucous nasal discharge. A leukopenia, which was most severe around the second to third day, was present during the febrile stage. The differential counts indicated a greater decrease in total neutrophils than in total lymphocytes. This was more marked (12%) in calves infected with Nebraska (C-1) agent. Toward the end of the febrile period the calves developed a diarrhea. These observations compare favorably with those of Barner et al. (1960) and Claflin et al. (1961). Barner et al. (1960), however, reported constipation rather than diarrhea developing in calves infected with the North Dakota (BMD) agent.

The average thermal and leukocytic responses observed in calves infected with the various agents used in this study are compared in Figures 63 and 64.

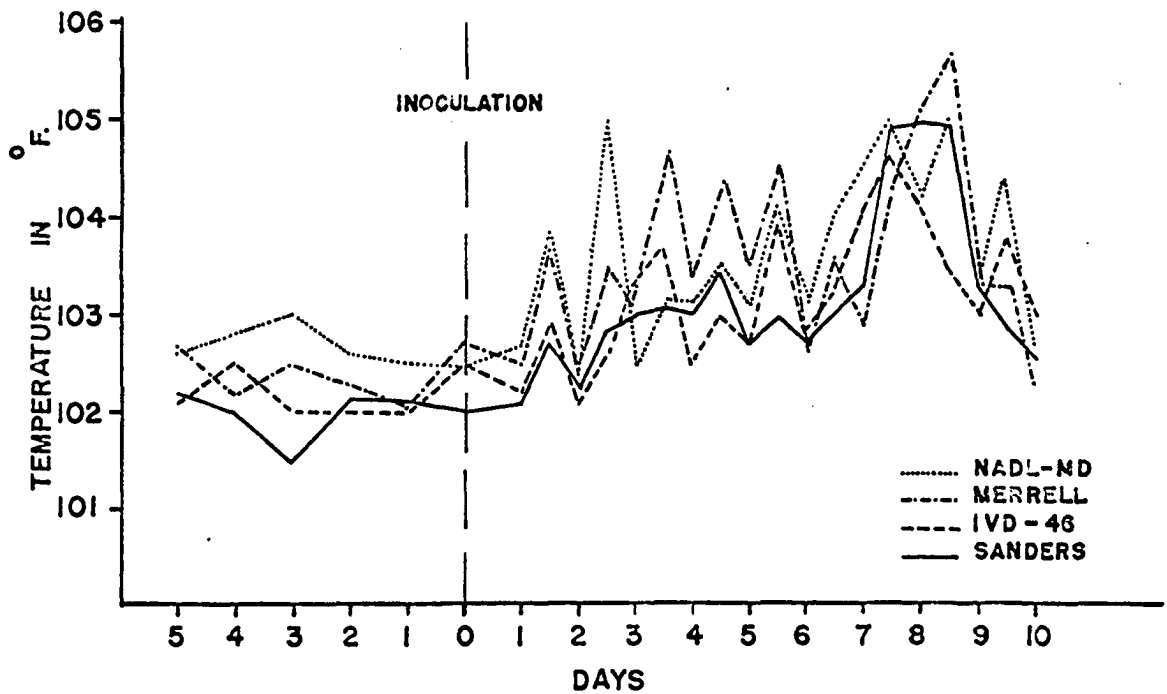
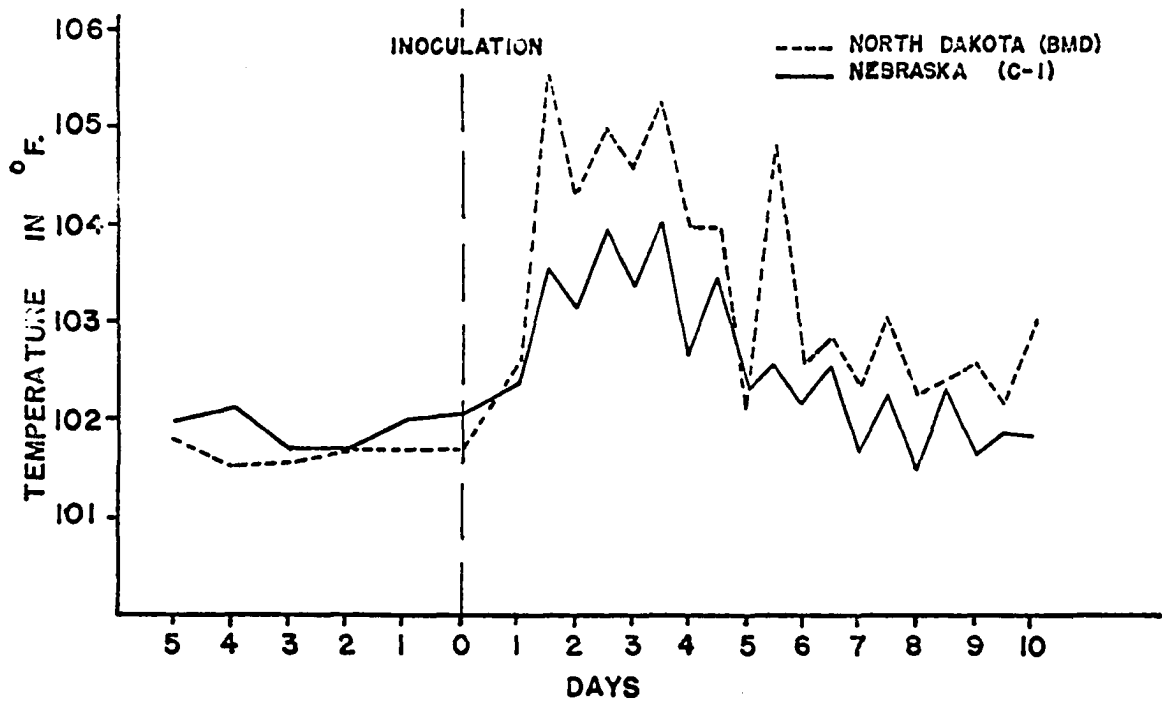
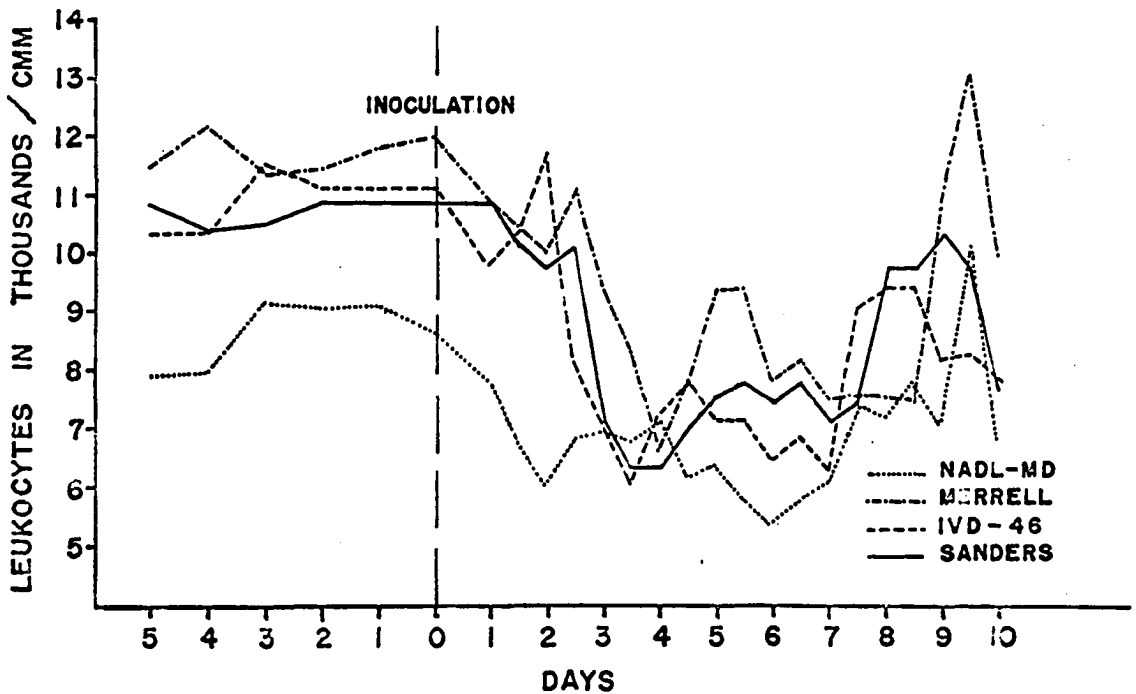
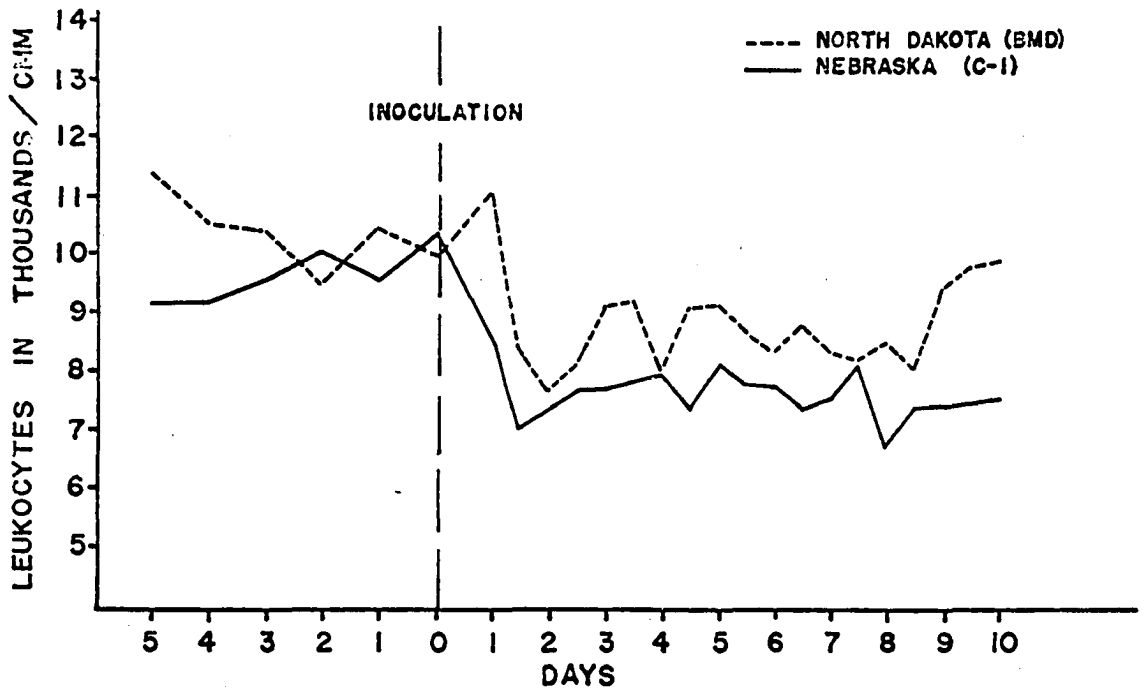


FIGURE 63. A COMPARISON OF THE THERMAL RESPONSES FOLLOWING INOCULATION WITH NEBRASKA (C-1), NORTH DAKOTA (BMD), MERRELL, SANDERS, NADL-MD, OR IVD-46 AGENTS. THE AVERAGE VALUES FROM FIGURES 1 THROUGH 6 ARE COMPARED.



**FIGURE 64.** A COMPARISON OF THE LEUKOCYTE RESPONSES FOLLOWING INOCULATION WITH NEBRASKA (C-1), NORTH DAKOTA (BMD), MERRELL, SANDERS, NADL-MD, OR IVD-46 AGENTS. THE AVERAGE VALUES FROM FIGURES 1 THROUGH 6 ARE COMPARED.

## Pathology

The gross pathologic changes produced in calves were similar for the Sanders, Merrell, IVD 46 and NADL-MD agents. Erosions of the esophagus were seen only in calves infected with the IVD 46 and NADL-MD agents. Although esophageal erosions were not seen in experimental Sanders infection in this study, they were frequently observed by Richter (1962). Esophageal lesions have not been reported in experimental Merrell infections. Perhaps this results from a strain variance as esophageal erosions were not observed in any of the affected animals in the herd where the Merrell agent was isolated (Tyler, 1960). Experience has shown that esophageal erosions may be absent in about one third of the field cases of mucosal disease. Although not grossly detectable, erosions of the rumen mucosa were invariably observed microscopically in cases having gross esophageal erosions.

The abomasal lesions were mild and consisted primarily of very shallow, irregular erosions of the mucosa. In no case did the lesions resemble those described for field cases of mucosal disease. Carlson et al. (1957) observed a greater response in this organ with experimental virus diarrhea cases. He reported congestion, edema, hemorrhage and erosions.

The most striking and consistent lesion was a mild to marked catarrhal enteritis. Peyer's patches and the mesenteric lymph nodes were swollen and edematous. These observations are almost identical with those reported by Richter (1962) for the Sanders agent and by Carlson et al. (1957) for experimental virus diarrhea.

Although edema was occasionally seen in the mesentery, excessive amounts of a fibrin-rich fluid in the body cavities as reported by

Richter (1962) were not observed.

In general, the lesions observed in these infections were similar to those described by Olafson et al. (1946) for experimental virus diarrhea, but more marked than those reported by Baker et al. (1954) for the same disease.

Histologic evaluation of tissues taken from experimentally infected calves revealed further similarities between the Sanders, Merrell, IVD 46 and NADL-MD agents. The most consistent and marked changes occurred in the lymphatic tissues. A mild to marked exhaustion of the lymphoid elements in Peyer's patches and in the germinal centers of the lymph nodes was invariably present. Nuclear debris and a proteinaceous, fibrinoid residue indicated that the loss of lymphocytes in these areas was caused by the necrotic activity of the disease agent. Accompanying the loss of lymphoid cells was an increase in macrophages. Whether these cells originated from proliferation of fixed macrophages or by infiltration from other areas could not be determined. In early cases the macrophages contained large quantities of cellular debris in their cytoplasm. Edema was also a prominent feature of these lesions.

In the Peyer's patches edema was most pronounced in the submucosa adjacent to the lymphoid tissue and in the spaces between the individual nodules. Accumulations of edematous fluid was also observed in the sub-capsular space of lymph nodes. In both cases this fluid was rich in neutrophils and fibrin. Similar lesions in lymphoid tissue were reported by Trapp (1960) in natural cases of mucosal disease. Richter (1962) found similar lesions in experimental Sanders infection as did Carlson et al. (1957) in calves infected experimentally with virus diarrhea.

Mild lymphoid depletion of the Malpighian corpuscles was observed in the spleen. Ramsey (1956) and Trapp (1960) observed similar but more severe lesions in field cases of mucosal disease. Carlson et al. (1957) reported only mild depletion of the germinal centers in acute cases of experimental virus diarrhea. Richter (1962) observed no active degeneration of the Malpighian corpuscles but felt that perhaps a mild depletion of the centers had occurred. Baker et al. (1954) reported no evidence of histologic change in the lymphoid tissues in cases of experimental virus diarrhea.

The significance of the accumulation of neutrophils around the Malpighian corpuscles is not understood. It has been the author's observation that neutrophils may normally be found in this area but not in such high concentrations. Rooney (1957) did not attempt to explain his observation of this reaction in field cases of mucosal disease. Trapp (1960) believed that the reaction was secondary in nature and not related to damage of the splenic lymphoid tissue.

The accumulation of large quantities of blood pigment without the presence of free iron indicates an improper functioning of the reticuloendothelial system of the spleen. Such a failure could result from either depletion of macrophages from the spleen or inability of diseased cells to phagocytize and reduce the hemoglobin to its constituent parts. Since a depletion could not be detected and practically no free iron was observed, the latter suggestion seems more plausible. In contradiction, Rooney (1957) and Trapp (1960) both reported the presence of increased amounts of hemosiderin and free iron in sections of the spleen taken from field cases of mucosal disease. It was Trapp's belief that this was

a secondary response.

The intestinal lesions were primarily inflammatory in nature. They were characterized by hyperemia, edema and cellular infiltration of the lamina propria. Necrosis of the tips of the villi was commonly seen. Submucosal edema was prominent in the area adjacent to the Peyer's patches. Carlson et al. (1957) observed similar lesions in experimental virus diarrhea infection. They reported that the most severe reaction appeared in the duodenum. Except for more prominent necrosis of the tips of the villi in the duodenum, it was observed in this study that the most marked reaction occurred in the jejunum and ileum. This was true grossly as well as microscopically. Carlson also reported that the cellular infiltrate was composed principally of lymphocytes. In this study the predominant cell was the eosinophil with lymphocytes and macrophages also contributing. Richter (1962) noted little other than edema and hypersecretion of mucus in his sections of the intestinal tract from cases of experimental Sanders infection. The intestinal lesions were merely suggestive of those described by Ramsey (1956) in field cases of mucosal disease.

Mild hyperemia and edema of the lamina propria were the principal lesion seen in the abomasum. The edema caused a noticeable separation of the glands. It was felt that the loss in parietal and chief cells was probably initiated by pressure atrophy from the edema. The loss of surface epithelium was hard to evaluate. Enzymatic digestion might have been responsible for most of the loss. It has been the author's experience that unless sections taken from the stomach or intestinal tract are rapidly fixed after death, digestion of the surface epithelium



will occur. Carlson et al. (1957) working with experimental virus diarrhea and Richter (1962) working with experimental Sanders infection described similar changes in the abomasum. The marked cystic, atrophic and degenerative changes in the mucosa of field cases of mucosal disease as reported by Ramsey (1956) were not observed.

Esophageal and rumen lesions were seen in several calves infected with the IVD 46 and NADL-MD agents. Multiple necrotic foci and erosions were observed in the epithelium. Initially the lesions were seen as small collections of hypertrophied cells. These cells underwent hydropic degeneration and eventual dissolution with the formation of vesicle-like structures. The vesicles were transformed to pustules as neutrophils invaded the necrotic areas. Extension to deeper layers of the epithelium and to the surface followed this stage. Rupture of the pustules produced erosion of the epithelial surface. A similar description of esophageal lesions as seen in experimental Sanders infection, experimental virus diarrhea, natural cases of mucosal disease and rinderpest has been reported respectively by Richter (1962), Carlson et al. (1957), Ramsey (1956), and Maurer et al. (1955).

Microfoci of hepatic necrosis were frequently seen. These lesions were usually invaded by three to five neutrophils. As the hepatic cells began to regenerate, lymphocytes replaced the neutrophils. Lymphocytic infiltrations generally did not exceed twelve to fifteen cells. Very minimal infiltrations of lymphocytes were also noted in the portal triads. In addition to microfoci of necrosis, Rooney (1957) also reported extensive fatty degeneration in liver sections obtained from field cases of mucosal disease. Ramsey (1956) and Carlson et al. (1957) also reported focal

necrotic hepatitis in natural cases of mucosal disease.

The significance and pathogenesis of these lesions are not understood. In an attempt to further evaluate these lesions, liver sections from several apparently healthy calves were added to the study. Tissues were obtained from two to four month old calves at the Rath Packing Company, Waterloo, Iowa. Additional sections were also selected from those used in the investigation of a focal hepatitis by Getty (1946). It was interesting to find that the majority of these sections contained lesions similar to those described in calves infected with the mucosal disease-viral diarrhea and IBR agents. This observation suggests that these lesions are either nonspecific entities or it lends credence to serologic surveys which have found the incidence of viral diarrhea and IBR antibodies in the native cattle population to be greater than fifty per cent.

Although these lesions may seem insignificant, the possibility exists that these small areas of necrosis may furnish an ideal environment for more serious pathogens such as Spherophorus necrophorus. Necrobacillosis of the liver has been commonly observed in cattle after mucosal disease has occurred in a herd.

As far as the digestive tract and lymphatic tissues were concerned the gross and histopathologic changes produced by the North Dakota (BMD) and Nebraska (C-1) agents were similar to those produced by the four preceding agents. The tissue response, however, was generally less severe in calves infected with these two agents. Differences noted in these calves were a lack of lesions in the esophagus and rumen, little evidence of necrosis in lymphatic tissue and the presence of necrotic foci in the adrenal cortices. Focal necrosis of the liver was also

generally more severe with these two agents. The only report on pathologic changes produced by these agents was made by Barner et al. (1960) in their work with the North Dakota (BMD) agent. Their observations were, in general, compatible with those presented in this study.

Although the work with the IBR virus was very limited, it helped significantly in evaluating the North Dakota (BMD) and Nebraska (C-1) agents. As has been shown before, the clinical disease resulting from the inoculation of the IBR virus depends largely on the portal of entry. For example, intranasal and intratracheal inoculations produce a respiratory disease whereas intravaginal inoculations result in a localized infection of the vaginal mucosa (Gillespie et al. 1958). Baker et al. (1960) observed that intravenous inoculation or oral administration of IBR virus in very young calves resulted in a disease primarily of the upper alimentary system. Focal areas of necrosis were seen in the mucosa from the mouth through the forestomachs, and also in the liver, lymph nodes, kidneys and spleen. Abinanti and Plumer (1961) reported on a conjunctivitis produced by intrapalpebral inoculation of the IBR virus. In fact, it was their feeling that under field conditions the majority of cattle affected by the IBR virus probably develop nothing more extensive than a conjunctivitis. An encephalitic syndrome was recognized in Australian cattle by French (1962). The agent was isolated in cell culture and the condition was reproduced experimentally by intracerebral inoculations. The agent was later shown to be a strain of the IBR virus.

Still another manifestation of the IBR virus has been revealed in this present study. The intravenous inoculation of IBR virus (Colorado strain, North Dakota (BMD) strain and Nebraska (C-1) strain) into three

to four month old calves produces a disease that is primarily enteric in nature. It is characterized clinically by a mild depression and pyrexia followed by diarrhea. Pathologically it results in an acute catarrhal enteritis, mild depletion of lymphatic tissues and multiple focal areas of necrosis in the adrenal cortices. Control calves inoculated intranasally with the Colorado strain developed none of the enteric symptoms or lesions. Instead, the typical respiratory disease as described by McKercher et al. (1955) and Gillespie et al. (1957) was observed. It is interesting to note that the adrenal necrosis appears only with intravenous inoculation. This observation was first made by Webster and Manktelow (1959) and indirectly by Barner et al. (1960) in their work with the North Dakota (BMD) agent. With the number of times that the IBR virus has been given by the intravenous route, it is interesting that this lesion has not been reported more often. It is especially so since adrenal necrosis has been used by Armstrong et al. (1961) as one of the criteria for placing the IBR virus in the Herpesvirus group.

#### Combined Inoculations

Combined inoculations of the various agents were used in the hope that synergistic relationship might exist between two or more of the agents. In general this aspect of the work was unrewarding. Two exceptions, however, are noteworthy. In the first one out of seven trials with combinations of the Sanders and Merrell agents a very marked reaction occurred. It was more severe in every respect than would be expected from the inoculation of either agent by itself. The most striking manifestation was the fibrino-necrotic areas in the Peyer's patches. In all the trials in this study this one most closely

resembled the field syndrome of mucosal disease. Why this combination was effective in only one trial has not been explained. Perhaps the reaction was due to factors other than the combination of the agents.

The other exception concerns the combination of the Sanders and North Dakota (BMD) agents. The calves infected with this combination of agents developed symptoms and lesions typical and atypical of both syndromes. The symptoms that suggested a different syndrome were the prolonged leukopenia and pyrexia. Diarrhea was more severe than seen with either agent alone. The esophageal, rumen and omasal erosions had not been seen in calves infected by either agent singly. However, reports of such lesions have been made for both the Sanders agent (Richter 1962) and the IBR agent (Baker et al. 1960). With these observations and the fact that the North Dakota (BMD) and Nebraska (C-1) strains of the IBR virus were presumedly isolated from field cases of mucosal disease, it would appear that further study of this relationship should be made.\*

#### Concluding Statements

In consideration of the similarity of the clinical, hematologic, pathologic and immunologic characteristics of the Sanders, Merrell, IVD 46 and NADL-MD agents, it would appear that these agents are closely related. Likewise, it is evident that the North Dakota (BMD), Nebraska (C-1) and IBR agents are related to each other. There is no evidence of immunologic relationship between the two groups of agents. If one

---

\*The recent isolation of a virus serologically related to the IBR virus from a field case of mucosal disease in Iowa would add further emphasis to this suggestion. The isolation was made by J. B. Gratzek, D.V.M., Department of Veterinary Hygiene, College of Veterinary Medicine, Iowa State University of Science and Technology, Ames, Iowa.

considers only the experimental syndromes resulting from intravenous inoculation of the agents, similarities in the clinical, hematologic and pathologic changes are readily apparent. These observations compare favorably with the serologic studies of Kniazeff and Pritchard (1960). They are also in general agreement with the serologic, immunologic and clinical evaluations of Taylor et al. (1963).

Although this study has added further evidence to the relationship of various mucosal disease and viral diarrhea isolants, it has done little to clarify the variability of the different syndromes as they are seen in the field. Mucosal disease is routinely differentiated from viral diarrhea on the basis of its higher mortality, lower morbidity, prolonged course in a herd, and greater severity of lesions. The lesions in the abomasum and Peyer's patches are particularly characteristic for mucosal disease. It is difficult to believe that such marked differences are within the realm of strain variation. It would seem more likely that some factor or combination of factors greatly influence the eventual syndrome resulting from an infection of a mucosal disease-viral diarrhea agent. It is suggested that further investigation of this complex be directed toward the recognition of such factors.

## SUMMARY

1. Six isolants were selected from the mucosal disease-viral diarrhea complex for a comparative in vivo study. Isolants from the field syndrome of mucosal disease included the Sanders, Merrell, NADL-MD, North Dakota (BMD) and Nebraska (C-1) agents. The IVD 46 strain represented the viral diarrhea isolants. A Colorado strain of the infectious bovine rhinotracheitis (IBR) virus was added for clarification when it became apparent that the North Dakota (BMD) and Nebraska (C-1) agents were strains of the IBR virus.

2. The agents were compared on the basis of the clinical, hematologic, immunologic, gross and histopathologic responses in experimental calves.

3. Ninety-four male Holstein calves ranging from 3 to 4 months in age were used.

4. The clinical and hematologic responses to inoculations of the Sanders, Merrell, IVD 46 or NADL-MD agents were similar. These responses were characterized by a biphasic pyrexia with peaks occurring on the third and seventh days postinoculation. Depression, mucous nasal discharge, anorexia, and diarrhea were visible symptoms during the febrile phase of the disease. An absolute neutropenia and lymphopenia occurring between the temperature peaks characterized the leukocytic responses. Rapid recovery followed the cessation of the pyrexia on the ninth day postinoculation.

5. Calves inoculated with the North Dakota (BMD) or Nebraska (C-1) agents responded similarly. Clinically these calves developed a monophasic temperature elevation which persisted from the second to the

fifth day postinoculation. During this time and until the seventh day postinoculation depression, anorexia, mucous nasal discharge and diarrhea were also noted. An absolute neutropenia and lymphopenia characterized the leukopenia which persisted from the second through the ninth day following inoculation. The calves recovered soon after the temperature returned to preinoculation levels.

6. Calves were euthanatized between six and thirteen days after inoculation for pathologic evaluation. Regardless of the agent the most consistent gross lesion was a catarrhal enteritis. Small, linear esophageal erosions were observed in calves inoculated with the IVD 46 and NADL-MD agents. Multiple foci of necrosis in the adrenal cortices were an additional observation in calves infected with North Dakota (BMD) or Nebraska (C-1) agents.

7. Sections were routinely taken from the esophagus, rumen abomasum, duodenum, jejunum, ileum, colon, mesenteric lymph nodes, spleen, thymus, adrenal gland, liver and kidneys of the euthanatized calves. Similar tissues were obtained from twenty apparently healthy cattle for comparison controls.

8. Microscopic evaluation of sections from Sanders, Merrell, IVD 46 or NADL-MD infected calves revealed that the most regular and severe lesions occurred in the lymphoid tissue. These lesions consisted of lymphoid depletion, necrosis and fibrinoid residue in the germinal centers. They were most pronounced in the Peyer's patches. Leukocytic infiltration of the lamina propria and focal areas of necrosis were regularly seen in the intestinal sections. Necrotic foci leading to pustules and eventual erosions were seen in the esophageal and rumen



epithelium of those calves infected with the IVD 46 and NADL-MD agents.

9. The microscopic examination of lesions resulting from an infection of the North Dakota (BMD) or Nebraska (C-1) agents revealed a similarity to the lesions produced by the Sanders, Merrell, IVD 46 and NADL-MD agents. Lymphoid depletion, however, was very mild and evidence of lymphoid necrosis was rarely seen. A lesion not observed in other infections was multiple focal caseous necrosis of the adrenal cortex. Erosions of the epithelium of the esophagus and rumen were not observed.

10. The IBR virus was inoculated intravenously into one calf and intranasally into two other calves. The intravenous inoculation resulted in a clinical and pathologic syndrome indistinguishable to that produced by the North Dakota (BMD) or Nebraska (C-1) agents. The intranasally infected calves developed symptoms and lesions involving only the upper respiratory tract.

Adrenal necrosis and enteric lesions were seen only in the calf inoculated intravenously with the IBR virus.

11. Combined inoculations of the Sanders agent with the Merrell, IVD 46 or NADL-MD agents resulted in an infection that was little different from that produced by a single inoculation of either agent. An exception was observed in one trial of a combination of the Sanders and Merrell agents. Both the clinical and pathologic response was more severe than has been recorded for either agent. Of all the infections in this study, this one most closely resembled the field syndrome of mucosal disease.

12. Simultaneous inoculations of the Sanders and North Dakota (BMD) agents resulted in a condition that was more marked than single inoculations

of either agent. It was characterized by a prolonged clinical course and erosions in the epithelium of the esophagus, rumen and omasum.

13. Cross protection tests revealed an immunologic relationship between the Sanders, Merrell, IVD 46 and NADL-MD agents. The North Dakota (BMD) and Nebraska (C-1) agents were also found to be immunologically related. Immunologic relationship between the two groups of agents, however, was not observed.

14. Considering the clinical, pathologic, immunologic and hematologic observations, it appears that the Sanders, Merrell, IVD 46 and NADL-MD agents are closely related. Similarly the North Dakota (BMD), Nebraska (C-1) and IBR agents are related. Although no immunologic relationship exists between the two groups of agents, similarities are observed in the clinical, hematologic and pathologic responses produced by these agents.

## LITERATURE CITED

- Abinanti, F. R. and Plumer, G. J. 1961. The isolation of infectious bovine rhinotracheitis virus from cattle affected with conjunctivitis-observations on the experimental infection. *American Journal Veterinary Research*. 22:13-17.
- Armed Forces Institute of Pathology. 1957. *Manual of histologic and special staining technics*. Washington D. C., Author.
- Armstrong, J. A., Pereira, H. G. and Andrews, C. H. 1961. Observations on the virus of infectious bovine rhinotracheitis and its affinity with the Herpesvirus group. *Virology*. 14:276-285.
- Baker, J. A., McEntee, K. and Gillespie, J. H. 1960. Effects of infectious bovine rhinotracheitis-infectious pustular vulvoaginitis (IBR-IPV) virus on newborn calves. *Cornell Veterinarian*. 50:156-170.
- Baker, J. A., York, C. J., Gillespie, J. H. and Mitchell, G. B. 1954. Virus diarrhea in cattle. *American Journal of Veterinary Research*. 15:525-531.
- Bakos, K. and Dinter, Z. 1960. Identification of a bovine mucosal disease virus isolated in Sweden as Myxovirus parainfluenza 3. *Nature*. 185:549-550.
- Barner, R. D., Whiteman, C. E., Cunningham, C. H., Rothenbacher, H. J. and Church, C. C. 1960. Mucosal disease of cattle. Unpublished mimeo paper presented at the NC-34 Technical Committee meeting, Brookings, South Dakota, October 1960. East Lansing, Michigan, Michigan Agricultural Experiment Station, Michigan State University.
- Beckenhauer, W. H., Brown, A. L., Lidolph, A. A. and Norden, C. J., Jr. 1961. Immunization of swine against hog cholera with a bovine enterovirus. *Veterinary Medicine*. 56:108-112.
- Benjamin, M. M. 1958. *Outline of veterinary clinical pathology*. 1st ed. Department of Pathology and Bacteriology, Fort Collins, Colorado, College of Veterinary Medicine, Colorado State University.
- Carlson, R. G., Pritchard, W. R. and Doyle, L. P. 1957. The pathology of virus diarrhea of cattle in Indiana. *American Journal Veterinary Research*. 18:560-568.
- Childs, T. 1946. X-disease in cattle-Saskatchewan. *Canadian Journal Comparative Medicine*. 10:316-319.

Claflin, R. M., Gillette, K. G., Gustafson, D. P., Moses, H. E. and Taylor, O. O. N. 1961. Mucosal diseases of cattle. Unpublished Mimeo paper presented at the NC-34 Technical Committee meeting, Lafayette, Indiana, October 1961. Lafayette, Indiana, School of Veterinary Science and Medicine, Purdue, University.

Darbyshire, J. H. 1960. A serological relationship between swine fever and mucosal disease of cattle. *Veterinary Record*. 72:331.

Dow, C., Jarrett, W. F. H. and McIntyre, W. I. M. 1956. A disease of cattle in Britain resembling the virus diarrhea-mucosal disease complex. *Veterinary Record*. 68:620-623.

Fister, H. J. 1950. Manual of standardization procedures for spectrophotometric chemistry. New York, New York, Standard Scientific Supply Corporation.

French, E. L. 1962. Relationship between infectious bovine rhinotracheitis (IBR) virus and a virus isolated from calves with encephalitis. *Australian Veterinary Journal*. 38:555-556.

Getty, Robert. 1946. The histopathology of a focal hepatitis and of its termination ("sawdust" and "telang" liver) in cattle. *American Journal of Veterinary Research*. 7:437-449.

Gillespie, J. H. and Baker, J. A. 1959. Studies on virus diarrhea. *Cornell Veterinarian*. 49:439-443.

Gillespie, J. H., Baker, J. A. and McEntee, K. 1960. A cytopathogenic strain of virus diarrhea virus. *Cornell Veterinarian*. 50:73-79.

Gillespie, J. H., Baker, J. A. and Wagner, W. C. 1958. The relationship of infectious pustular vulvovaginitis virus to infectious bovine rhinotracheitis virus. *United States Livestock Sanitary Association Proceedings*. 1958. 119-126.

Gillespie, J. H., Coggins, L., Thompson, J. and Baker, J. A. 1961. Comparison by neutralization tests of strains of virus isolated from virus diarrhea and mucosal disease. *Cornell Veterinarian*. 51:155-159.

Gillespie, J. H., Lee, K. M. and Baker, J. A. 1957. Infectious bovine rhinotracheitis. *American Journal Veterinary Research*. 18:530-535.

Gillespie, J. H., Madin, S. H. and Darby, N. 1962. Cellular resistance in tissue culture induced by non-cytopathogenic strains to a cytopathogenic strain of virus diarrhea virus of cattle. *Society Experimental Biology and Medicine Proceedings*. 110:248-250.

Gillespie, J. H., Madin, S. H. and Darby, N. B. 1963. Studies on virus diarrhea virus of cattle, with special reference to its growth in tissue culture and its ether susceptibility. *Cornell Veterinarian*. 53:276-281.

Gutekunst, D. E. and Malmquist, W. A. 1963. Separation of a soluble antigen and infectious particles of bovine viral diarrhea viruses and their relationship to hog cholera. *Canadian Journal Comparative Medicine and Veterinary Science*. 27:121-123.

Hermodsson, S. and Dinter, Z. 1962. Proportions of bovine virus diarrhoea virus. *Nature (London)*. 194:893-894.

Huck, R. A. 1957. Mucosal disease complex. *Journal Comparative Pathology and Therapeutics*. 67:267-276.

Kniazeff, A. J., Huck, R. A., Jarrett, W. F. H., Pritchard, W. R., Ramsey, F. K., Schipper, I. A., Stober, Von M. and Liess, B. 1961. Antigenic relationships of some bovine viral diarrhea-mucosal disease viruses from the United States, Great Britain and West Germany. *Veterinary Record*. 73:768-769.

Kniazeff, A. J. and Pritchard, W. R. 1960. Antigenic relationships in the bovine viral diarrhea-mucosal disease complex. *United States Livestock Sanitary Association Proceedings*. 1960:344-350.

Lee, K. M. and Gillespie, J. H. 1957. Propagation of virus diarrhea of cattle in tissue culture. *American Journal Veterinary Research*. 18: 952-953.

Maurer, F. D., Jones, T. C., Easterday, B. and Detray, D. 1955. The pathology of rinderpest. *American Veterinary Medical Association Proceedings*. 92:201-211.

McKercher, D. G., Moulton, J. E. and Jasper, D. E. 1954. Virus and virus-like disease entities new to California. *United States Livestock Sanitary Association Proceedings*. 1954:260-269.

McKercher, D. G., Moulton, J. E., Kendrick, J. W. and Saito, J. 1955. Recent developments on upper respiratory disease of cattle. *United States Livestock Sanitary Association Proceedings*. 1955:151-167.

Miller, N. J. 1955. Infectious necrotic rhinotracheitis of cattle. *American Veterinary Medical Association Journal*. 126:463-467.

Noice, F. and Schipper, I. A. 1959. Isolation of mucosal disease virus by tissue cultures in mixture 199, Morgan, Morton and Parker. *Society Experimental Biology and Medicine Proceedings*. 100:84-86.

Olafson, P., MacCallum, A. D. and Fox, F. H. 1946. An apparently new transmissible disease of cattle. *Cornell Veterinarian*. 36:205-213.

Olafson, P. and Rickard, C. G. 1947. Further observations on the virus diarrhea (new transmissible disease of cattle). *Cornell Veterinarian*. 37:104-106.

Pritchard, W. R. 1955. The mucosal disease of cattle--epizootiology, symptomatology, and experimental studies. American Veterinary Medical Association Proceedings. 1955:37-42.

Pritchard, W. R. and Carlson, R. G. 1957. Symposium on the mucosal disease complex. III. Virus diarrhea in cattle. American Veterinary Medical Association Journal. 130:383-385.

Pritchard, W. R., Carlson, R. G., Moses, H. E. and Taylor, D. B. 1955. Virus diarrhea and mucosal disease. United States Livestock Sanitary Association Proceedings. 1955:173-188.

Pritchard, W. R. and Kniazeff, A. J. 1958. Bovine enteroviruses. United States Livestock Sanitary Association Proceedings. 1958:1-6.

Pritchard, W. R., Taylor, D. B., Moses, H. E., Doyle, L. P. 1954. A virus diarrhea of cattle. Unpublished multilithed paper presented as a portion of the detailed annual report for 1954, Department of Veterinary Science, Indiana Agricultural Experiment Station, Purdue University. Project No. 724. Lafayette, Indiana, Department of Veterinary Science, Purdue University.

Ramsey, F. K. 1956. Pathology of a mucosal disease of cattle. (A printed monograph) Ames, Iowa, Department of Veterinary Pathology. Iowa State University of Science and Technology.

Ramsey, F. K. and Chivers, W. H. 1953. Mucosal disease of cattle. North American Veterinarian. 34:629-633.

Richter, W. R. 1962. The pathology of experimental infection produced by a filterable agent, isolated from a field case of mucosal disease of cattle. Unpublished M.S. thesis. Ames, Iowa, Library, Iowa State University of Science and Technology.

Robson, D. S., Gillespie, J. H. and Baker, J. A. 1960. The neutralization test as an indicator of immunity to virus diarrhea. Cornell Veterinarian. 50:503-509.

Rooney, J. R. II, 1957. Pathology of a bovine mucosal-type disease. American Journal Veterinary Research. 18:283-291.

Sahli, H. 1905. Diagnostic Methods. (Translation) 4th ed. Philadelphia. (Original not available; cited in Fister, H. J. 1950). Manual of standardized procedures for spectrophotometric chemistry. p. 10.1. New York, New York, Standard Scientific Supply Corporation.

Schipper, I. A., Eveleth, D. F., Shumard, R. F. and Richards, S. H. 1955. Mucosal disease of cattle. Veterinary Medicine. 50:431-435.

- Schipper, I. A. and Holm, E. 1961. Mucosal disease of cattle. Unpublished mimeo paper presented at the NC-34 Technical Committee meeting, Lafayette, Indiana, October 1961. Fargo, North Dakota, Department of Veterinary Science, North Dakota State University.
- Schroeder, R. J. and Moys, M. D. 1954. An acute upper respiratory infection of dairy cattle. American Veterinary Medical Association Journal. 125:471-472.
- Sheffy, B. E., Coggins, L., and Baker, J. A. 1961. Protection of pigs against hog cholera with virus diarrhea virus of cattle. United States Livestock Sanitary Association Proceedings. 1961:347-353.
- Taylor, D. O. N., Gustafson, D. P. and Claflin, R. M. 1963. Properties of some viruses of the mucosal disease-virus diarrhea complex. American Journal Veterinary Research. 24:143-149.
- Trapp, A. L. 1960. Pathology of the blood-vascular and lymphatic systems of cattle affected with mucosal disease. Unpublished Ph.D. thesis. Ames, Iowa, Library, Iowa State University of Science and Technology.
- Tyler, D. E. 1960. The influence of avitaminosis A on the susceptibility of calves to mucosal disease. Unpublished M.S. thesis. Lafayette, Indiana, Library, Purdue, University.
- Underdahl, N. R., Grace, O. D. and Hoerlein, A. B. 1957. Cultivation in tissue culture of cytopathogenic agent from bovine mucosal disease. Society Experimental Biology and Medicine Proceedings. 94:795-797.
- United States Department of Agriculture. Agricultural Research Service. 1956. Mucosal disease complex. United States Department of Agriculture Report ARS 22-27.
- Walker, R. V. L. and Olafson, P. 1947. Failure of virus diarrhea of cattle to immunize against rinderpest. Cornell Veterinarian. 37:107-111.
- Webster, R. G. and Manktelow, B. W. 1959. Some observations on infectious bovine rhinotracheitis in New Zealand. New Zealand Veterinary Journal. 7:143-148.
- Wheat, J. D., McKercher, D. G. and York, C. J. 1954. Virus diarrhea in California. California Veterinarian. Nov.-Dec. 1954. Original not available; reprint available from Wheat, J. D., Davis, California, School of Veterinary Medicine, University of California.

## ACKNOWLEDGEMENTS

The author is grateful for the patient counsel and encouragement given by Dr. F. K. Ramsey during the course of this study. It has been a pleasure to work with a committee that has been so considerate and cooperative. Other members of the committee are Dr. R. J. Bryan, Dr. R. A. Packer, Dr. M. W. Sloss, Dr. Robert Getty and Dr. I. A. Merchant. Dr. B. W. Kingrey also served on the committee until he left the staff on September 1, 1963.

Others contributed in many different ways to aid in the successful completion of this study. Thanks go especially to the following people:

Mrs. P. A. Owenson, Mrs. P. A. Haensley, Mrs. Grace Faber, Mrs. D. N. Williams, Mrs. S. K. Simon and Mrs. Marie Provost for their excellent and patient assistance in the laboratory procedures.

Dr. J. P. Kunesh, Dr. W. R. Snider, Dr. J. K. Burt, Dr. M. A. Elliott, Dr. G. A. Sutter, Mr. D. A. Schulke, Mr. M. D. Roepke, Mr. H. M. Bonnes, and Mr. C. W. Laursen for their capable work with the calves.

Dr. M. J. Van Der Maaten for his cooperation in supplying infective cell culture materials.

Dr. C. P. Peter for his aid in the serologic classification of the IBR virus strains.

Dr. M. W. Sloss and Dr. P. B. Mullenax for their constructive criticism of the thesis manuscript.

Mr. L. A. Facto and his staff for the excellent photography.

Mr. D. J. Hillmann for his careful and lucid preparation of the graphic illustrations.



Mrs. R. E. Peterson for the commendable quality of the typing of the final manuscript.

A special vote of thanks goes to my wife, La Von, for her capable assistance in the preparation of the rough drafts and final manuscript of the thesis. Her patience and encouragement have been especially appreciated.